

CASE REPORT

Chondroma of Hyoid Bone Presenting as a Parapharyngeal Mass: A Case Report

Arulalan Mathialagan¹, Pattayil Keeranghat Pearly², Ravi S Manogaran³, Amit K Keshri⁴

ABSTRACT

Aim: We aim to describe an unusual pathology presenting as a parapharyngeal mass and its successful surgical management.

Background: Chondromas of hyoid bone are rare in occurrence; only a few cases have been reported in the literature. We are reporting the first case of hyoid chondroma presenting as parapharyngeal mass.

Case description: We report a 45-year-old male presented with a neck mass on the right submandibular gland region with a change in voice. The computed tomographic scan of the patient, showed a heterogeneous mass in the parapharyngeal region, seemed to be originating from the greater cornu of the right hyoid bone. The tumor was removed completely using Trans-cervical approach with part of the hyoid bone.

Conclusion: Chondroma is a rare tumor of the hyoid, and it should be kept in mind for the differential diagnosis of parapharyngeal tumors.

Keywords: Chondroma, Hyoid bone, Parapharyngeal space.

Journal of Postgraduate Medicine, Education and Research (2020): 10.5005/jp-journals-10028-1404

BACKGROUND

Parapharyngeal space tumors are uncommon ones that account for 0.5% of head and neck neoplasms. Histologically, the most common tumor of parapharyngeal space is a pleomorphic adenoma, followed by paraganglioma.¹ The other uncommon tumors in parapharyngeal spaces are neurofibroma, meningioma, and lymphoma.²⁻⁵ Chondroma in parapharyngeal space is an infrequent entity. Until now, only one case of chondroma of parapharyngeal space was reported, which was de novo in origin from soft tissues of parapharyngeal space.⁶ In this study, we were saying the first case of chondroma, which was originating from hyoid and presented as a parapharyngeal mass.

CASE DESCRIPTION

A 45-year-old male laborer presented with right side upper neck swelling for 2 years which was insidious in onset, gradually progressive in size, and also noted a change in voice for 8 months. There was no history of difficulty in swallowing and breathing. On physical examination, a 3 × 2 cm well-defined firm nontender mass with restricted mobility was present in the right submandibular gland region. On video laryngoscopy, there was mucosal covered bulge involving right tonsillar fossa, vallecular, and hypopharynx. Epiglottis displaced posteriorly and toward the left side. Contrast-enhanced computed tomography was done and a well-defined lobulated mass with solid and cystic component extending from greater cornu of the hyoid bone (Fig. 1A) and filling right parapharyngeal space (Fig. 1B) was observed, solid part showed mild enhancement, and the submandibular gland was normal. Fine-needle aspiration was done, which was inconclusive.

Tumor was excised under general anesthesia through trans-cervical approach (Fig. 2A). Tumor was dissected from surrounding tissues; it has a well-defined plane and attached with right side greater cornu of the hyoid bone (Fig. 2B) which was removed along with adequate margin and sent for histopathological examination. Size of resected specimen was 7.5 × 6 × 5.5 cm. Histopathology of the tumor showed well-encapsulated mass comprising of the lobule

¹⁻⁴Department of Neurosurgery, Neuro-otology Unit, Sanjay Gandhi Postgraduate Institute of Medical Sciences, Lucknow, Uttar Pradesh, India

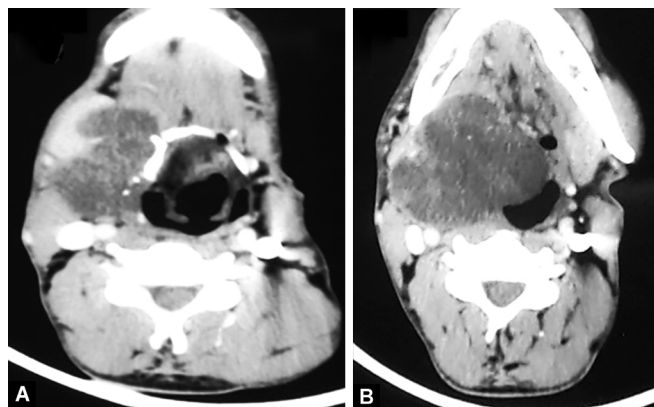
Corresponding Author: Ravi S Manogaran, Department of Neurosurgery, Neuro-otology Unit, Sanjay Gandhi Postgraduate Institute of Medical Sciences, Lucknow, Uttar Pradesh, India, Phone: +91 7010599665, e-mail: dravisankarpgi@gmail.com

How to cite this article: Mathialagan A, Pearly PK, Manogaran RS, et al. Chondroma of Hyoid Bone Presenting as a Parapharyngeal Mass: A Case Report. J Postgrad Med Edu Res 2020;XX(X):1-2.

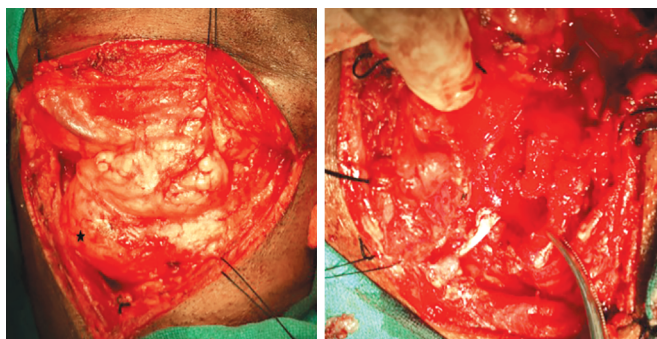
Source of support: Nil

Conflict of interest: None

of chondrocyte embedded in a chondromyxoid matrix and specks of calcification without any evidence of nuclear polymorphism (Fig. 3). The patient was asymptomatic after 6 months of follow-up, and the voice became normal.



Figs 1A and B: (A) Heterogenous mass filling the submandibular space arising from the right greater horn of hyoid; (B) Mass filling right parapharyngeal space with displacement of vallecular



Figs 2A and B: (A) Exposure of submandibular gland and the tumor in relation to the gland (Star); (B) Site of origin over the hyoid bone

DISCUSSION

Chondroma is also known as enchondroma. Enchondromas are cartilage-capped bony projection that usually grows from heterotopic cartilage cell rests.⁷ In our case, the probable site of origin is the cartilage of the hyoid bone because the greater cornu of hyoid bone develops from the third branchial arch, and the posterior portion of greater cornu is cartilage in nature.² Although etiology of this tumor is not known, possibly mechanical stress from the ligaments and muscle attached to the greater cornu of hyoid might be the cause.

Hyoid chondroma have been very rare, and only few case reports were reported.²⁻⁴ Hyoid chondromas commonly present as external neck masses;^{3,5} in our case, it presented with external as well as huge parapharyngeal mass with a change in voice due to oropharyngeal bulge. One example of parapharyngeal chondroma arising de novo from parapharyngeal soft tissue.⁶ Apart from clinical examination, radiological evaluation is necessary for assessing the origin, size, and true extent of the lesion and help us in planning the management of these tumors.^{8,9} Magnetic resonance can give better soft tissue delineation. However, radiological workup cannot help in differentiating chondroma from chondrosarcoma.⁸

The primary differential diagnosis for chondroma is chondrosarcoma because of their similar clinical behavior. Chondrosarcoma differs from chondroma by its invasive nature and nuclear pleomorphism.⁸⁻¹⁰ Chondrosarcoma should be suspected whenever size exceeds more than 5 cm.¹⁰ In this case, although the volume was more than 7 cm, there is no evidence of sarcoma histologically.

Surgery is the primary mode of treatment for hyoid chondromas. Treatment requires complete removal along with adequate removal of hyoid bone because of the risk of recurrence and malignant transformation. Regular follow-up is mandatory to rule out possible recurrence.

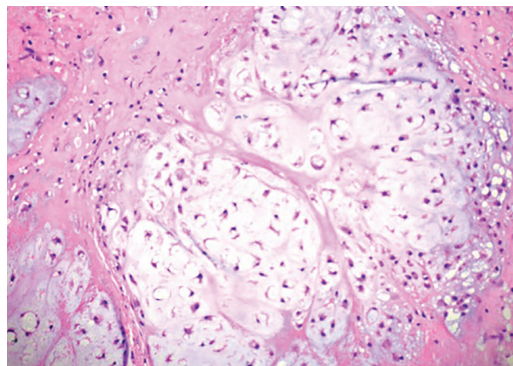


Fig. 3: Chondromyxoid matrix on histopathological examination

CONCLUSION

Chondroma is a rare tumor of the hyoid, and it should be kept in mind for the differential diagnosis of parapharyngeal tumors. A high index of suspicion is required when a firm mass fills the parapharyngeal space and presents as external neck swelling and oropharyngeal bulge.

REFERENCES

1. Patadia S, Keshri A. Otolaryngology benign parapharyngeal tumours: surgical intricacies by transcervical approach. *Am J Otolaryngol* 2016;6:1-5.
2. Nakagawa Y, Ishibashi K, Asada K, et al. Chondroma of the hyoid bone: a case report. *Oral Surg Oral Med Oral Pathol Oral Radiol Endod* 1999;88(3):333-336. DOI: 10.1016/S1079-2104(99)70038-7.
3. Ozcan I, Ozcan KM, Selcuk A, et al. Hyoid chondroma presenting as an external neck mass. *J Craniofac Surg* 2007;18(5):1184-1187. DOI: 10.1097/scs.0b013e3181572aea.
4. Grayson A, Bain M. Juxtacortical chondroma of the hyoid bone. Report of a case *Arch Otolaryngol* 1967;86(6):679-680. DOI: 10.1001/archotol.1967.00760050681015.
5. Saydam L, Köybasi S, Kutluay L. Laryngeal chondroma presenting as an external neck mass. *Eur Arch Otorhinolaryngol* 2003;260(5):239-241. DOI: 10.1007/s00405-002-0563-x.
6. Wang DH, Guan XL, Xiao LF, et al. Soft tissue chondroma of the parapharyngeal space: a case report. *J Laryngol Otol* 1998;112(3):294-295. DOI: 10.1017/S0022215100158396.
7. Wani AA, Zargar JI, Ramzan AU, et al. Isolated enchondroma of atlas. *Turk Neurosurg* 2011;21:226-229.
8. Wang SJ, Borges A, Lufkin RB, et al. Chondroid tumors of the larynx: computed tomography findings. *Am J Otolaryngol* 1999;20(6):379-382. DOI: 10.1016/S0196-0709(99)90077-7.
9. Wiese JA, Viner TF, Rinehart RJ, et al. Cartilaginous tumor of the larynx. *Ann Otol Rhinol Laryngol* 1992;101(7):617-619. DOI: 10.1177/000348949210100714.
10. Nojima T, Unni KK, McLeod RA, et al. Periosteal chondroma and periosteal chondrosarcoma. *Am J Surg Pathol* 1985;9(9):666-677. DOI: 10.1097/0000478-198509000-00006.