

# Management of Rigid Post-poliomyelitis Equinocavovarus Deformities: A Brief Review

Rajiv Shah<sup>1</sup>, Siddharth Sharma<sup>2</sup>, Shivam R Shah<sup>3</sup>

## ABSTRACT

Foot and ankle deformities are frequent in patients with post-polio residual paralysis (PPRP), and can be attributed to abnormal muscle balance, abnormal posture, gravitation forces, and continued walking over the deformed foot. Equinocavovarus is the most common foot and ankle deformity in PPRP patients. Late presenting or neglected deformities can lead to gait abnormalities, abnormal pressure areas, increased energy expenditure, and arthritis of foot joints. Management of post-poliomyelitis equinocavovarus requires an in-depth understanding of the pathoanatomy as well as the interplay of muscle dynamics.

**Keywords:** Equinocavovarus deformity, Foot and ankle deformity, Neglected foot and ankle deformities, Poliomyelitis.

*Journal of Foot and Ankle Surgery (Asia Pacific) (2021): 10.5005/jp-journals-10040-1173*

## BACKGROUND

Although poliomyelitis is rare in developed countries, cases with late sequela of poliomyelitis are common in developing countries.<sup>1</sup> Foot and ankle deformities in poliomyelitis can be attributed to abnormal muscle balance, abnormal posture, gravitation forces, and continued walking over the deformed foot.<sup>1-3</sup> Late presenting or neglected poliomyelitis deformities of the foot and ankle can lead to gait abnormalities, abnormal pressure areas, increased energy expenditure, and joints' arthritis.<sup>4</sup> The joint contractures, stress fractures, and callosities are also common.<sup>5</sup> The clinician must carry out a thorough clinical evaluation for the successful management of neglected foot and ankle deformities in poliomyelitis.<sup>1,4,5</sup> Equinocavovarus foot deformity is one of the most challenging deformities to manage.<sup>6</sup> In this article, we discuss in brief, the management of a rigid post-poliomyelitis equinocavovarus deformity.

## PATHOGENESIS AND PATHOANATOMY

Equinocavovarus deformity is characterized by equinus and varus deformity of the ankle, cavus deformity of the midfoot plus associated claw, and hammertoe deformities of the forefoot. The primary reason is muscle weakness and muscle imbalance between extrinsic and intrinsic.<sup>7-9</sup> Weak tibialis anterior is countered by strong peroneus longus leading to hyperplantarflexion of the first metatarsal. The long toe extensors try to compensate for weak tibialis anterior, leading to an imbalance between extrinsic and intrinsic extensors resulting in dorsiflexion of fewer toes at the metatarsophalangeal joint. The activity of long flexors contributes to the clawing of toes plus increased cavus of the midfoot. Stronger tibialis posterior pulls the foot into plantarflexion and inversion.<sup>7-9</sup>

## NATURAL HISTORY

The functional consequence of equinocavovarus deformity is limited dorsiflexion at the ankle. Reasons being short tendoachilles, acquired a horizontal position of talus in the ankle mortise, and a cavus deformity. The limitation of dorsiflexion at the ankle may lead to hyperextension deformity at the knee. The subtalar joint has a limit of pronation with resultant impingement between the medial

<sup>1</sup>Department of Foot and Ankle Orthopaedics, Sunshine Global Hospital, Vadodara, Gujarat, India

<sup>2</sup>Department of Foot and Ankle Orthopaedics, Post Graduate Institute of Medical Education and Research, Chandigarh, Punjab, India

<sup>3</sup>Department of Orthopaedics, Baroda Medical College, Vadodara, Gujarat, India

**Corresponding Author:** Rajiv Shah, Department of Foot and Ankle Orthopaedics, Sunshine Global Hospital, Vadodara, Gujarat, India, Phone: +91 9825011487, e-mail: rajivortho@gmail.com

**How to cite this article:** Shah R, Sharma S, Shah SR. Management of Rigid Post-poliomyelitis Equinocavovarus Deformities: A Brief Review. *J Foot Ankle Surg (Asia Pacific)* 2021;XX(X):1-7.

**Source of support:** Nil

**Conflict of interest:** None

malleolus and the talus. Navicular is pulled medially to create bony impingement medially. Talar neck osteophytes are expected in late presenting cases. The ankle not being able to tolerate varus and supination forces develops varus tilting.

Initial untreated supple deformity tends to get converted into a rigid deformity over the years. Walking over the foot's lateral border leads to the formation of corns and callosities in long-standing cases. Stress fractures of the lateral column of the foot may be the end result.

## INDICATIONS FOR CORRECTION

Every symptomatic case, either with a supple or with a rigid equinocavovarus foot deformity, must be corrected. The aim is to get a foot in a plantigrade position. Corrective orthotics may work for a flexible deformity in childhood, but compliance may be an issue. Long-standing and progressive deformity requires to be addressed surgically. The presence of painful corns and callosities at the forefoot's plantar aspect and over the foot's lateral border also demands immediate attention. Pain in the knee and back due to faulty weight transmission indicates a surgical correction of the

deformity. The deformity correction is also indicated in a patient with bilateral involvement with paralyzed hips and knees. Surgical correction in such a situation is deemed for better fitting of calipers.

## CONTRAINDICATIONS

Non-compliant patients, patients with multiple comorbidities, and patients with vascular compromise are not the candidates for surgery.

## PRINCIPLES OF CORRECTION

Conservative modalities like orthotics, physiotherapy, stretching, and bracing should always be tried first.<sup>1</sup> Surgical management is undertaken only after a failure of conservative modalities. Not every case requires surgical management.<sup>1</sup> The patient's age, occupation, functional demands, and deformity pattern are denominators for surgical intervention.<sup>1,4,5</sup> Based on the clinical and radiological evaluation findings, a plan of surgical management is devised. The sequence of surgical procedures is also planned. The goal of the treatment is to get a painless, stable, plantigrade foot.<sup>10-13</sup> Corrective osteotomies, soft tissue releases, tendon transfers, and arthrodesis are the mainstay of surgical management.<sup>1,4,14</sup>

- The surgeon's wisdom shall prevail in decision-making, whether to go for a single-stage correction or to go for a multistage correction. The surgeon should also decide whether he desires acute correction with open surgery or a gradual correction with the Ilizarov apparatus.<sup>15-19</sup> Correction of shortening should also be considered in indicated cases.<sup>15-19</sup>
- If the foot's deformity in the form of the equinus is compensating for weak knee muscles, correcting the same might lead to knee problems leading to hand-to-knee gait. Either such a deformity should be left alone, or a preliminary knee procedure in the form of correction of knee flexion contracture with soft tissue procedures or an extension osteotomy of the knee should be done (Fig. 1).<sup>20,21</sup>
- Before contemplating surgery, preoperative planning in the form of soft tissue releases, the degrees of wedge correction of bones, patterns of tendon transfers, and the sequence of

surgery should be done and documented. The surgical plan must consider unforeseen circumstances for which a plan B should be on hand. The clinician must define the flexibility of equinovarus deformity as a surgical correction plan is based on the flexibility of deformity. The flexible deformities require soft tissue procedures in the form of releases, tendon transfers, and also the addition of bony procedures like osteotomies. The arthrodesis is reserved until the age of maturity. The majority of these deformities on a long-standing course become fixed ones. The fixed deformities require more bony procedures in the form of osteotomies and corrective arthrodesis.

- Correction always proceeds from proximal to distal in direction. Soft tissue correction always precedes bony correction. Before moving on to the next step during the surgical correction, a repeat evaluation of deformity must be carried out. Thus, deformity correction is a stepwise and sequential process. The drawing of proposed incisions before surgery helps the surgeon in maintaining sufficient skin bridges between incisions. Tendon transfers are carried out at last after completion of bony procedures. Correction through bony wedges is started in steps beginning with removing smaller wedges and moving on to extend the resection as needed. This avoids overcorrection. Ensuring complete removal of articular cartilage and precise joint preparation would only prevent the non-union of arthrodesis. Even cases corrected with arthrodesis require the addition of tendon transfers to balance the foot. Careful planning of skin incisions would only avoid difficulty in skin closure.

## PREOPERATIVE ASSESSMENT AND PLANNING

- Complete exposure of the whole lower limb up to the hip is essential for clinical evaluation, carried in standing, sitting, and walking positions. Over and above foot and ankle, deformity evaluation covers evaluating the spine, hip, and knee.
- The heel's position and the geometry of the medial longitudinal arch are evaluated on a medial side. The presence of corns, callosities, and pressure ulcers are documented on a lateral foot evaluation. Similarly, the plantar aspect of the forefoot

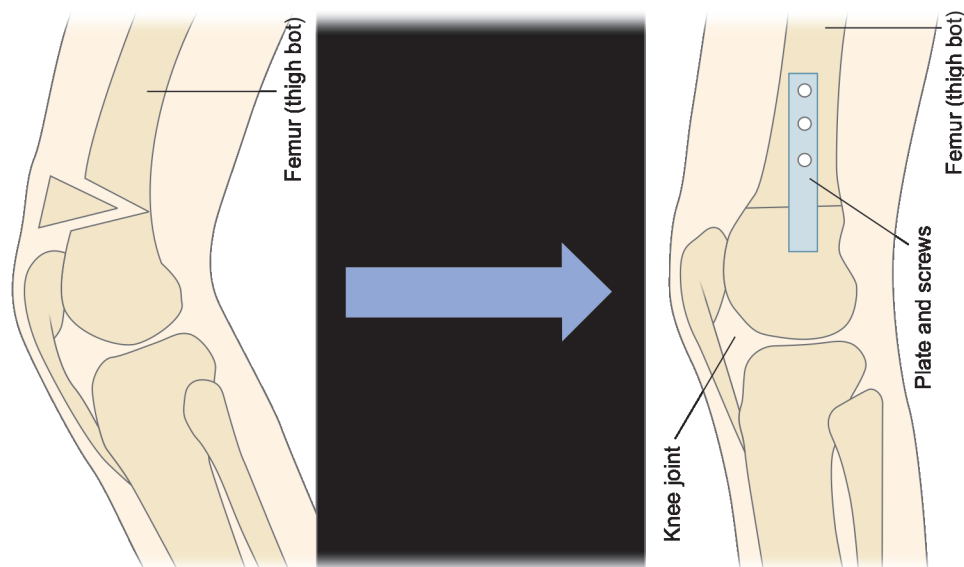


Fig. 1: Line diagram showing supracondylar extension osteotomy

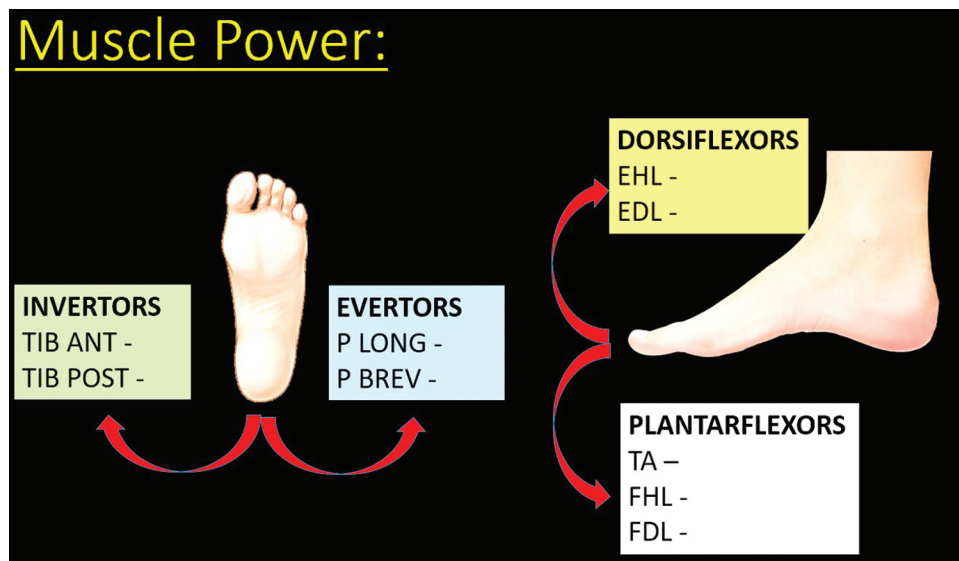
is examined for the presence of callus underneath metatarsal heads. Careful charting of the power of muscles of the ankle, foot, knee, and hip is vital. We routinely draw pictures of a lateral view of the foot and ankle, and a sole with a listing of muscles with their power. Such a picture makes the planning of muscle transfers swift (Fig. 2). Manipulation of every joint is done in sequence, starting from the hip and going down to the toes. Analysis of contractures and the ability of deformity to get corrected are vital. The neurovascular evaluation follows. Tendoachilles contracture is evaluated with a Silfverskiöld test. Coleman block test differentiating forefoot driven varus from hindfoot-driven varus. The last but most significant evaluation is of gait, footwear, and orthotics. The aim is to document deformity in all three planes, coronal, sagittal, and transverse planes, starting from the ankle, hindfoot, midfoot, and forefoot (Table 1). Video documentation of gait and a photograph of the shoe and orthotics is done. A drawing of the foot and ankle demonstrating deformity and pressure areas is worthwhile.

- Plain and weight-bearing radiographs of foot and ankle are obtained. Lateral view of the foot with ankle demonstrates signs of hindfoot varus, equinus, and midfoot cavus. The position of the first metatarsal vs other metatarsals is assessed. The joints

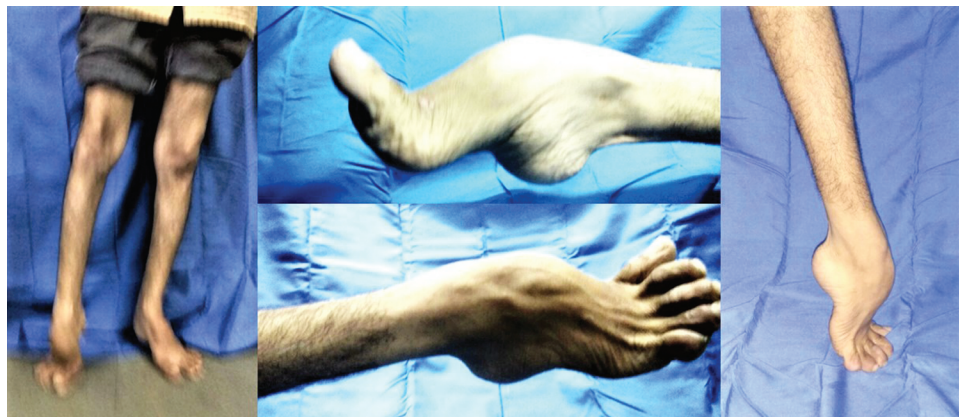
are evaluated for the presence of arthritis and bony structural changes. Radiographs of joints above plus a scanogram of the whole limb are essential for planning a correction. CT scan is rarely indicated. A recent trend is to get a 3D-printed bone model for assessing the deformity and doing a preoperative surgical rehearsal of correcting the deformity (Figs 3 and 4).

**Table 1:** A checklist for documentation of deformities

| Region      | Sagittal plane deformity | Coronal plane deformity | Transverse plane deformity | Combinations of deformities |
|-------------|--------------------------|-------------------------|----------------------------|-----------------------------|
| Spine       |                          |                         |                            |                             |
| Hip         |                          |                         |                            |                             |
| Knee        |                          |                         |                            |                             |
| Ankle       |                          |                         |                            |                             |
| Hindfoot    |                          |                         |                            |                             |
| Midfoot     |                          |                         |                            |                             |
| Forefoot    |                          |                         |                            |                             |
| Great toe   |                          |                         |                            |                             |
| Lesser toes |                          |                         |                            |                             |



**Fig. 2:** Picture of a chart to document the muscle power of the foot and ankle



**Fig. 3:** Clinical photographs of a case with bilateral equinovarus deformity



## SURGICAL TECHNIQUES

### The Sequence of Correction

We always begin with the correction of the hindfoot and move towards the forefoot. Equinus is corrected first, followed by hindfoot varus, midfoot cavus, drop of the first metatarsal, and correction of toes is undertaken at last.

### Approaches

Usually, standard approaches specific to a procedure are carried out. Figure 5 shows all standard approaches. In a long-standing, rigid equinovarus foot, either a talectomy with triple fusion or a pantalar fusion is contemplated; authors like to take an extensile midline anterior approach (Fig. 6). The approach runs 10 cm above the ankle, just lateral to the tibialis anterior tendon to the center of the ankle to the foot between the second and third metatarsals. The

skin and the subcutaneous tissue are incised in line with the incision taking care of the superficial peroneal nerve in the incision's distal part. With tibialis anterior retracted medially and extensor hallucis together with neurovascular structures retracted laterally, the incision is deepened up to the capsule of the ankle and talonavicular joints. This is an extensile approach and can be extended proximally as well as distally as per the requirement.

### Equinus

The degree of equinus decides the procedure for correction. By and large, open Z-shaped lengthening of tendoachilles is preferred. The lower transverse limb of Z is medial for varus deformities and is lateral for the valgus deformity (Fig. 7). Suppose correction of equinus is inadequate after lengthening of tendoachilles. In that case, releases of joint capsules of the ankle and subtalar joints are added. Further inadequate correction, partial or a complete

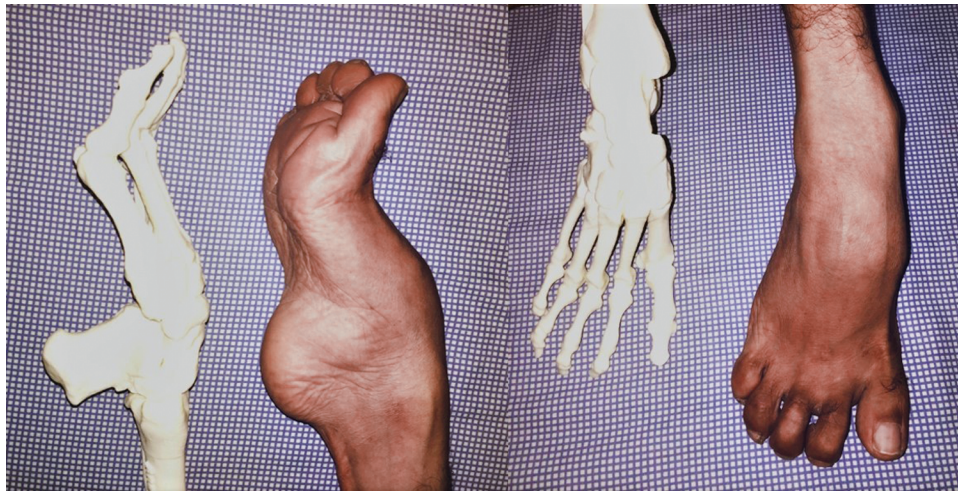

Fig. 4: 3D-printed model of bilateral equinovarus deformity of the case shown in Figure 3

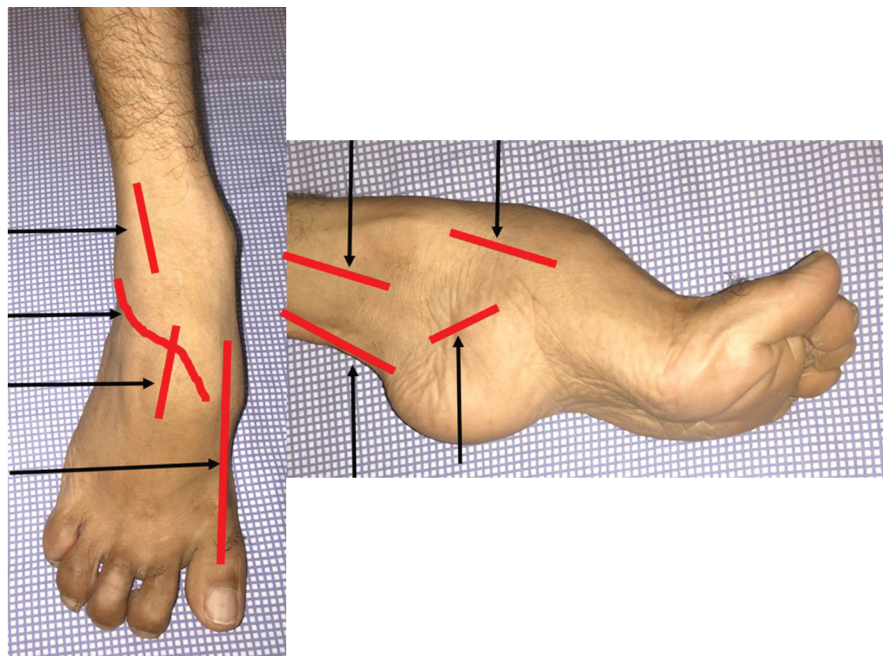


Fig. 5: Figure demonstrates incisions required for correction of rigid equinovarus deformity. (A – Incision for tendoachilles lengthening, B – Incision for plantar fascia release, C1–C4 – Incisions for tibialis posterior transfer, D – Incision for triple fusion, E – Incision for correction of claw deformity of hallux)



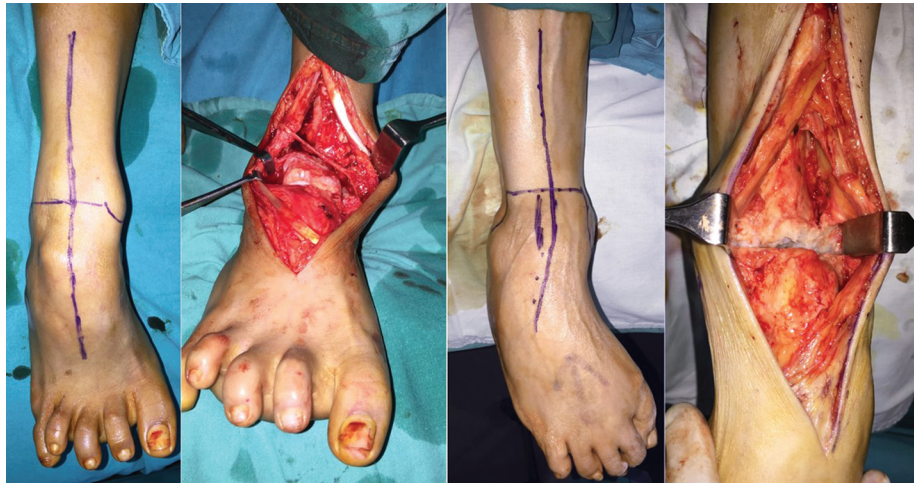

Fig. 6: Intraoperative photographs of equinovarus deformity cases treated with an anterior extensile approach

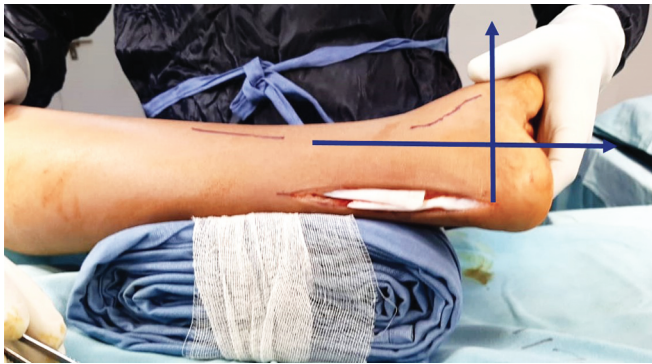


Fig. 7: Intraoperative photograph of correction of equinus deformity with Z lengthening of tendoachilles

talectomy, and Lambrinudi type fusion are added. Surprisingly, many deformities get adequately corrected by just lengthening of tendoachilles, and further procedures are not required. Brief description of crucial procedures to correct equinus follows:

#### *Tendoachilles Lengthening*

An 8- to 10-cm-long incision is made starting from the insertion of the Achilles tendon. The skin and the paratenon are divided with the same incision to expose the Achilles tendon. A Z-lengthening of the tendon is performed starting laterally at the upper end and ending medially at the distal end. The ankle joint is forcibly manipulated in dorsiflexion to get the correction of the equinus. Suturing of both the cut tendon's limbs is done with the ankle in dorsiflexion and at last.

#### *Lambrinudi Fusion*

An S-shaped lateral approach begins 2 cm distal to the lateral malleolus, reaching the lateral aspect of the talus's head. The sural nerve is encountered in the incision's proximal portion, while the superficial peroneal nerve is encountered in the incision's distal portion. Superficial and deep dissection is carried up to the talonavicular and subtalar joints taking care of these nerves. The subtalar and the calcaneocuboid joints are reached with the plantar reflection of tendons of peroneal and distal reflection of extensor digitorum brevis. Anteriorly the talonavicular joint is reached. The wedges are removed from all three joints (subtalar, talonavicular,

and calcaneocuboid), and deformity is corrected. Final fixation can be carried out with screws, staples, and plates after an image check.

### **VARUS OF HEEL**

Heel varus requires correction with a Dwyer osteotomy. Dwyer osteotomy may be combined with lateral translation osteotomy of the calcaneus for a significant heel varus deformity. Authors have also corrected significant heel varus deformity by a corrective subtalar joint fusion with a laterally based wedge. Description of a technique of a Dwyer osteotomy follows.

#### **Dwyer Osteotomy**

A skin incision is made above the tendons of the peroneal and vertical to the calcaneus axis. The sural nerve is protected. After exposure of the calcaneus's lateral wall, a laterally based wedge is resected with a saw. The medial cortex is not violated, and a greenstick fracture of the medial cortex is done to yield the correction. Temporary fixation is carried out with the use of k-wires. Final fixation with screws or a plate follows after image check.

#### **Cavus of Midfoot**

Equinus deformity has a close association with cavus deformity at the midfoot. Midfoot cavus should be addressed with a plantar fascia release. Cavus of significant type would require corrective basal osteotomies of all metatarsals or a midfoot osteotomy. Though midfoot osteotomies end up in a stiff foot, they are preferred because of the robust correction they yield at the deformity's apex. For the prevention of shortening at midfoot osteotomies, we like the Akron type of midfoot osteotomy (Fig. 8).<sup>22,23</sup> Description of plantar fascia release and midfoot osteotomy follows.

#### *Plantar Fascia Release*

A straight incision of 3–4 cm is made over the plantar medial border of the heel. Subcutaneous tissues are carefully divided, and the origin of the plantar fascia is exposed. With right-angled retractors in place, the plantar fascia's complete release is done with a sharp knife or scissor.

#### *Midfoot Osteotomy*

Two paralleled vertical incisions, one over the first ray and the other over the third ray, are taken over the foot's dorsum. Careful,

in-depth exposure protects superficial nerves and neurovascular. Cuneiform and cuboid are exposed subperiosteally. A distally convex osteotomy runs from the medial cuneiform to the cuboid. Once the osteotomy is completed, multiplanar correction of the foot can be achieved and checked under fluoroscopy. Fixation can be carried out with screws, wires, or plates.

### Forefoot Supination

Tibialis posterior transfer, either total or split, will compensate for this deformity. Long-standing rigid deformities may require corrective triple fusion. The technique of tibialis posterior transfer follows.

#### *Tibialis Posterior Transfer*

The tibialis posterior is harvested through a 4-cm long incision centered over the navicular tuberosity. The released tendon is retrieved at the level of the lower third of the leg through another incision. The tibialis posterior's tendon is then pulled out in an anterolateral incision at the leg through the hole in the interosseous membrane. Depending upon the muscle imbalance, the tibialis tendon is attached to the second or the third cuneiform. We pass tendon subcutaneously and not under the extensor retinaculum. The tendon is attached to bone by an interference screw.

### The Drop of the First Metatarsal

Plantarflexed first metatarsal is corrected with modified Jones procedure where the tendon of extensor hallucis longus is transferred to the neck of the first metatarsal together with arthrodesis of the first distal interphalangeal joint.<sup>24</sup> With a paralyzed extensor of the great toe, a more robust bony procedure

in the form of corrective dorsiflexion osteotomy, the first metatarsal base will be required. The senior author has preferred corrective Lapidus fusion at the first tarsometatarsal joint over the osteotomy. Description of the Jones procedure follows.

#### *Jones Procedure*

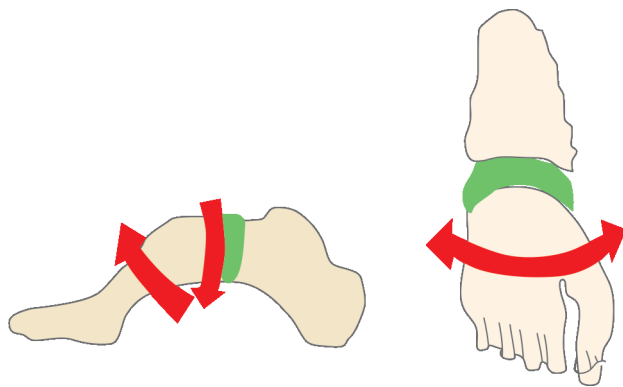
A long vertical incision runs over the first ray, starting from the distal interphalangeal joint until the first metatarsal base. The insertion of the extensor hallucis longus tendon is released as distal as possible, and the tendon is reflected. The cartilage of adjoining bony surfaces of the distal interphalangeal joint is denuded, and the distal interphalangeal joint's arthrodesis is carried out with screw fixation. A hole is drilled in the first metatarsal neck and is enlarged to accommodate the extensor hallucis longus tendon. Tendon is passed through the metatarsal neck and is tied over itself with the ankle in a neutral position and the first metatarsal held in maximum dorsiflexion.

### Toe Deformities

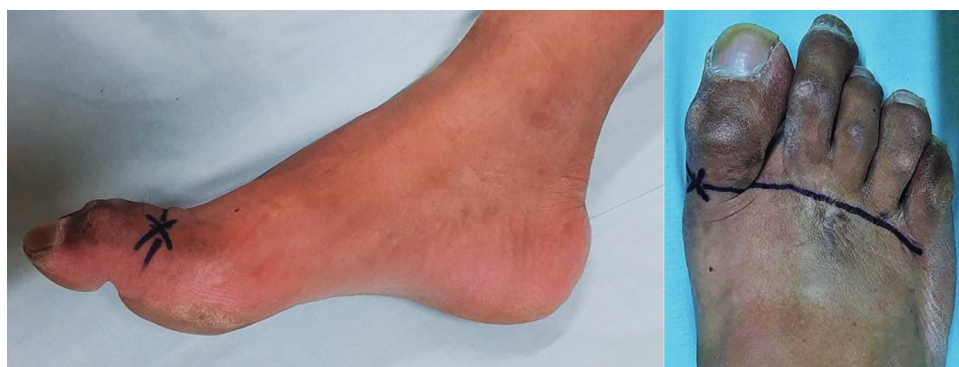Toe deformities produce significant disability in the form of corns, callosities, and painful gait (Fig. 9). Standing evaluation of toe deformities is vital to evaluate their flexibility and the involvement of the metatarsophalangeal joint. Flexible deformities of the toe require soft tissue balancing procedures in the form of transfer of deforming long flexor dorsally. Rigid deformities require arthrodesis of proximal and distal interphalangeal joints. Persistent dorsiflexion of the toe at the metatarsophalangeal joint is addressed with dorsal capsulotomy and extensor tendon lengthening. Advanced deformities require excision arthroplasty of the metatarsophalangeal joint. Flexion contracture at hallux is managed by a corrective fusion of the distal interphalangeal joint. Coronal plane hallux deformities are addressed with respective capsular releases and bony osteotomies.

### AFTERCARE

At the end of the procedures, fascial layers are closed with 1-0 Vicryl and subcutaneous tissues with 2-0 Vicryl. Skin is closed with interrupted non-absorbable sutures. A well-padded below-knee splint supports the limb, which is strictly elevated for a period of a week to 10 days. Sutures are removed at 12 to 14 days, and a complete below-knee plaster cast is applied for 6 weeks. At 6 weeks, the cast is removed; X-rays of the foot and ankle are obtained to learn about bony fusion status. Active, assisted, and passive range of motion physiotherapy is started after removal of plaster splint. Regular X-ray checks are done at the end of 4 weeks. Based on the status of the union, gradual weight bearing is permitted.



**Fig. 8:** Line diagrams showing Akron-type corrective midfoot osteotomy. Red arrows show directions of correction



**Fig. 9:** Clinical photograph of claw toes in the patient of residual poliomyelitis with equinovagovarus deformity

## COMPLICATIONS

Commonly encountered complications comprise skin closure issues, superficial to deep infection, pin tract infection, pressure sores, vessel or nerve injury, malunion, and non-union. Overcorrection or undercorrection may result in a flat foot, cavus foot, valgus ankle, or a calcaneus foot. Recurrence of deformity is a possibility.

## CONCLUSION

Management of post-poliomyelitis equinovarus requires an in-depth understanding of the pathoanatomy as well as the interplay of muscle dynamics. A careful and detailed preoperative examination is a must to identify and address all components of the deformity. The surgical management is tailored to the patient's deformity and functional needs. Although the surgical management of these cases is technically demanding, good to excellent results can be obtained with appropriate patient selection, and by paying meticulous attention to the surgical aspects involved in correction.

## REFERENCES

1. Dhillon MS, Sandhu HS. Surgical options in the management of residual foot problems in poliomyelitis. *Foot Ankle Clin* 2000;5(2):327–347.
2. Laffont I, Julia M, Tiffreau V, et al. Aging and sequelae of poliomyelitis. *Ann Phys Rehabil Med* 2010;53(1):24–33. DOI: 10.1016/j.rehab.2009.10.002.
3. Hecht ABH. *Deadly diseases and epidemics: polio*. 2nd ed., Infobase Publishing; 2009. pp. 8–10.
4. Faraj AA. Poliomyelitis: orthopaedic management. *Curr Orthop* 2006;20(1):41–46. DOI: 10.1016/j.cuor.2005.10.005.
5. Thompson DM, Calhoun JH. Advanced techniques in foot and ankle reconstruction. *Foot Ankle Clin* 2000;5(2):417–442.
6. Coleman SS. *Complex foot deformities in children*. Philadelphia: Lea and Febiger; 1983.
7. Dwyer FC. The present status of the problem of the pes cavus. *Cin Orthop Relat Res* 1975;109(106):254–275. DOI: 10.1097/00003086-197501000-00038.
8. Cole WH. The treatment of claw-foot. *J Bone Joint Surg* 1940;22:895–908.
9. Dwyer FC. Osteotomy of the calcaneus for pes cavus. *J Bone Joint Surg Br* 1959;41B(1):80–86. DOI: 10.1302/0301-620X.41B1.80.
10. Steindler A. The treatment of the flail ankle; panastagaloid arthrodesis. *J Bone Joint Surg*. 1923;5(2):284–294.
11. Faraj AA. Talonavicular joint arthrodesis for paralytic post poliomyelitis forefoot instability. *J Foot Ankle Surg* 1996;35(2):166–168. DOI: 10.1016/s1067-2516(96)80035-4.
12. Crego Jr C, McCarroll H. Recurrent deformities in stabilized paralytic feet: a report of 1100 consecutive stabilizations in poliomyelitis. *J Bone Joint Surg* 1938;20(3):609–620.
13. Acosta R, Ushiba J, Cracchiolo 3rd A. The results of a primary and staged pantalar arthrodesis and tibiototalcaneal arthrodesis in adult patients. *Foot Ankle Int* 2000;21(3):182–194. DOI: 10.1177/107110070002100302.
14. Faillace JJ, Leopold SS, Brage ME. Extended hindfoot fusions and pantalar fusions. History, biomechanics, and clinical results. *Foot Ankle Clin* 2000;5(4):777–798.
15. Grant AD, Atar D, Lehman WB. The Ilizarov technique in correction of complex foot deformities. *Clin Orthop Relat Res* 1992(280):94–103. DOI: 10.1097/00003086-199207000-00012.
16. Kirienko A, Peccati A, Abdellatif I, et al. Correction of poliomyelitis foot deformities with Ilizarov method. *Strategies Trauma Limb Reconstr* 2011;6(3):107–120. DOI: 10.1007/s11751-011-0111-6.
17. Kocaoğlu M, Eralp L, Atalar AC, et al. Correction of complex foot deformities using the Ilizarov external fixator. *J Foot Ankle Surg* 2002;41(1):30–39. DOI: 10.1016/s1067-2516(02)80007-2.
18. Grant AD, Atar D, Lehman WB. Ilizarov technique in correction of foot deformities: a preliminary report. *Foot Ankle* 1990;11(1):1–5. DOI: 10.1177/107110079001100101.
19. Huang SC. Leg lengthening by the Ilizarov technique for patients with sequelae of poliomyelitis. *J Formos Med Assoc* 1997;96(4):258–265. DOI: 10.1016/S0929-6646(10)60051-4.
20. Zouari O, Gargouri A, Jenzri M, et al. Supracondylar femoral extension osteotomy for knee flexion contracture correction in poliomyelitic conditions. *Rev Chir Orthop Reparatrice Appar Mot* 2001;87(4):361–366.
21. Men HX, Bian CH, Yang CD, et al. Surgical treatment of the flail knee after poliomyelitis. *J Bone Joint Surg Br* 1991;73(2):195–199. DOI: 10.1302/0301-620X.73B2.2005137.
22. Stapleton JJ, DiDomenico LA, Zgonis T. Corrective midfoot osteotomies. *Clin Podiatr Med Surg* 2008;25(4):681–690. DOI: 10.1016/j.cpm.2008.05.004, ix.
23. Weiner DS, Morscher M, Junko JT, et al. The Akron dome midfoot osteotomy as a salvage procedure for the treatment of rigid pes cavus: a retrospective review. *J Pediatr Orthop* 2008;28(1):68–80. DOI: 10.1097/bpo.0b013e31815a5fba.
24. Faraj AA. Modified Jones procedure for post-polio claw hallux deformity. *J Foot Ankle Surg* 1997;36(5):356–359. DOI: 10.1016/s1067-2516(97)80036-1.