

## CASE REPORT

# Primary Tuberculosis of the Ethmoids Mimicking Tolosa Hunt Syndrome: A Case Report

Nitya Subramanian<sup>1</sup>, Anil Kumar<sup>2</sup>, Neha Sood<sup>3</sup>, WVBS Ramalingam<sup>4</sup>

Received on: 17 December 2020; Accepted on: 06 June 2023; Published on: XX XXXX XXXX

## ABSTRACT

Incidence of primary sinonasal tuberculosis (TB) is only 1.8% of all cases of tuberculosis and among them the involvement of ethmoidal sinuses is very rare. The most common clinical presentation of sinonasal TB is that of persisting rhinosinusitis, resistant to usual treatment. We report a case of primary tuberculosis of the ethmoids and the orbit which presented with symptoms mimicking Tolosa Hunt syndrome (THS). Through this case we wish to highlight this rare clinical presentation of paranasal sinus tuberculosis and the subsequent management of this patient.

**Keywords:** Case report, Tuberculosis, Paranasal sinuses, Tolosa Hunt syndrome.

*Clinical Rhinology* (2020): 10.5005/jp-journals-10013-1388

## INTRODUCTION

In developing countries like India, incidence of extrapulmonary tuberculosis is very high. Among the extrapulmonary sites involvement of the paranasal sinuses is very rare seen in only 1.8% of all patients suffering from tuberculosis.<sup>1</sup>

Sinonasal tuberculosis (TB) usually occurs secondary to pulmonary TB following inhalation of infected particles. Occurrence of primary sinonasal TB is very rare owing to the protective actions of the sinonasal mucosa. Only forty cases have been reported worldwide until date. These have been attributed to inhalation of infected particles or traumatic digital inoculation.<sup>2</sup> Maxillary sinuses are the most commonly affected among the paranasal sinuses. The involvements of ethmoids are very rare.

Tolosa-Hunt syndrome (THS) is a painful condition characterized by hemicranial pain, retro-orbital pain, loss of vision, oculomotor nerve paralysis, and sensory loss in distribution of ophthalmic and maxillary division of trigeminal nerve.<sup>3</sup> Clinically this syndrome is simulated by multiple other disorders like trauma, vascular malformations, intracranial tumors, intracranial metastases, endocrine disorders, and inflammatory and infectious conditions. We report a case of primary tuberculosis of the ethmoids and the orbit which presented with symptoms mimicking THS. Through this case we wish to highlight this rare clinical presentation and the subsequent management of this patient.

## CASE DESCRIPTION

We report the case of a 25-year-old male who presented with severe pain in the right eye associated with swelling around the eye, with acute onset. He also complained of persisting diplopia of a few months duration with no complaints of diminution of vision or restriction of ocular movements. There were no complaints of headache, nasal blockage, nasal discharge, or epistaxis.

On examination, there was mild proptosis of right eye with ophthalmoplegia. Visual acuity was normal.

At another center, he was diagnosed clinically as Tolosa-Hunt syndrome and started on systemic steroids with no clinical improvement. However, subsequent MRI of the orbit and PNS revealed evidence of ill-defined enhancing soft tissue signal

<sup>1-4</sup>Department of ENT & Head & Neck Surgery, BLK Super Speciality Hospital, New Delhi, India

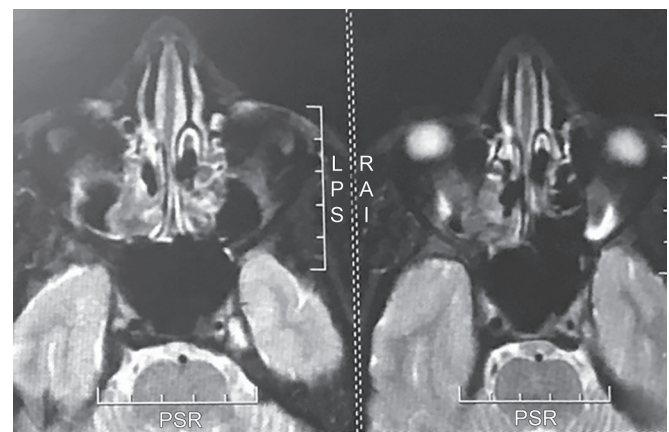
**Corresponding Author:** Nitya Subramanian, Department of ENT & Head & Neck Surgery, BLK Super Speciality Hospital, New Delhi, India, Phone: +91 9650764673, e-mail: tellnitya@rediffmail.com

**How to cite this article:** Subramanian N, Kumar A, Sood N, *et al.* Primary Tuberculosis of the Ethmoids Mimicking Tolosa Hunt Syndrome: A Case Report. *Clin Rhinol* 2020;xx(xx):xx-xx.

**Source of support:** Nil

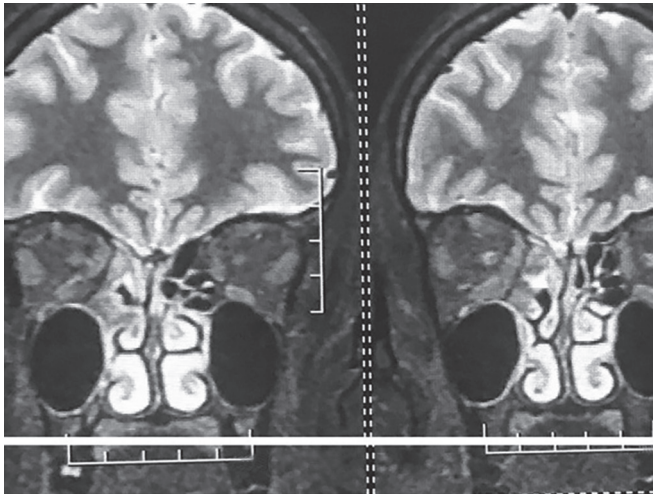
**Conflict of interest:** None

**Patient consent statement:** The author(s) have obtained written informed consent from the patient for publication of the case report details and related images.

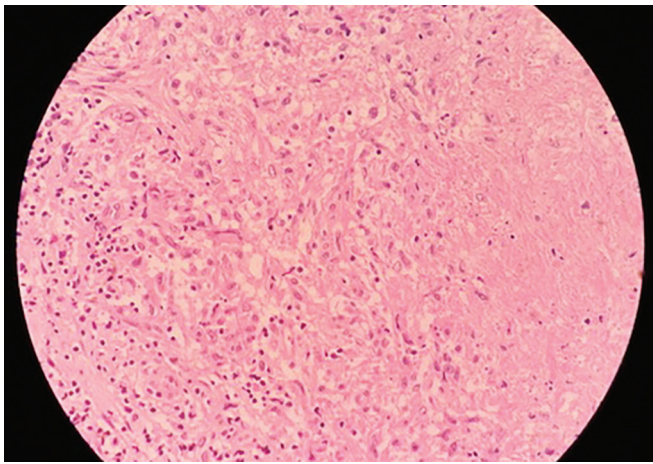


**Fig. 1:** MRI PNS and orbit-axial cut—showing soft tissue signal intensity in the right posterior ethmoid air cells extending to the posterior medial extraconal space of the right orbit

intensity in the right posterior ethmoid air cells extending to the posterior medial extraconal space of the right orbit adjacent to the inferior and medial rectus. This was associated with effacement of extraconal and surrounding fat (Figs 1 and 2).



**Fig. 2:** MRI PNS and orbit-coronal cuts—showing involvement of posterior ethmoids extending to the orbit with effacement of extraconal fat and surrounding fat



**Fig. 3:** The histopathological picture is suggestive of necrotizing epithelioid cell granulomas with inflammation

In light of these findings, the patient underwent endoscopic sinus surgery with orbital decompression under general anesthesia. Per-operatively, a firm mass with cartilaginous consistency was seen occupying the ethmoids on the right side communicating with the orbit which was removed and sent for HPE. Histopathological examination revealed evidence of necrotizing epithelioid cell granulomas with inflammation consistent with the diagnosis of TB (Fig. 3).

There was no evidence of pulmonary tuberculosis or focus of TB anywhere else in the body on further investigation. The patient was started on a standard antitubercular drug regimen (rifampicin, isoniazid, ethambutol, and pyrazinamide) following which the patient improved postoperatively. The patient has remained symptom-free one year after the completion of the antituberculous chemotherapy. In the median follow-up period of 2 years, the patient has had no evidence of recurrence and has remained disease free.

## DISCUSSION

Occurrence of primary sinonasal TB is very rare. It was first reported in 1761 by Morgagni.<sup>4</sup> Sinonasal tuberculosis can present in the form of three clinical variants. Most common among them is infection confined to the mucosa with polypoidal appearance. The next common form has bony involvement and fistula formation and the rarest form is hyperplastic with the formation of tuberculoma.<sup>5</sup>

Our patient had no nasal complaints and only presented with neurological manifestations. The initial evaluation in such a clinical scenario is aimed at exclusion of causes of painful ophthalmoplegia. The differential diagnosis includes neoplasms, infectious, inflammatory and vascular pathologies. Contrast-enhanced MRI with multiple views is the initial investigation of choice.<sup>6</sup>

The initial impression of THS, which was made based on clinical presentation was established to be secondary to lymphomatous infiltration seen in TB as confirmed by MRI and subsequent histopathological examination.

The treatment of sinonasal tuberculosis is surgical debridement followed by antituberculosis chemotherapy. The standard recommended protocol for patients with extrapulmonary tuberculosis is a 6- to 9-month regimen which includes two months of isoniazid, rifampicin, pyrazinamide, and ethambutol followed by 4–7 months of isoniazid and rifampicin. The long-term prognosis following treatment is generally favorable.<sup>7</sup>

## CONCLUSION

Tuberculosis of the nose and paranasal sinuses are so infrequent that it is virtually a forgotten entity and thus poses a diagnostic dilemma for clinicians. Through this case, we highlight this rare presentation of primary ethmoid and orbital tuberculosis presenting with neurological symptoms in the absence of nasal complaints.

## REFERENCES

1. Khan S, Pujani M, Jetley S. Primary nasal tuberculosis: Resurgence or coincidence – A report of four cases with review of literature. *J Lab Physicians* 2017;9(1):26–30. DOI: 10.4103/0974-2727.187921.
2. Kim KY, Bae JO, Park JS, et al. Primary sinonasal tuberculosis confined to the unilateral maxillary sinus. *Int J Clin Exp Pathol* 2014;7(2): 815–818. PMID: 24551309.
3. Peddi P, Gallagher KM, Chandrasekharan C. Tolosa-hunt syndrome in double-hit lymphoma. *Case Rep Oncol Med* 2015;2015:249891. DOI: 10.1155/2015/249891.
4. Butt AA. Nasal tuberculosis in the 20th century. *Am J Med Sci* 1997;313(6):332–335. DOI: [https://doi.org/10.1016/S0002-9629\(15\)40132-6](https://doi.org/10.1016/S0002-9629(15)40132-6).
5. International Headache Society, “The international classification of headache disorders,” *Cephalalgia* 2004;24. pp. 1–151.
6. Chaudhary V, Venu S, Deswal J. Painful ophthalmoplegia due to Tolosa-hunt syndrome: A case report. *Int J Med Sci Public Health* 2016;5(5):1045–1048. DOI: 10.5455/ijmsph.2016.13022016361.
7. Goguen LA, Karmody CS. Nasal tuberculosis. *Otolaryngol Head Neck Surg* 1995;113(1):131–135. DOI: <https://doi.org/10.1016/S0194-59989570156-7>.