CASE REPORT

A Rare Case of a Combined Laryngocele

Sanjay Gala[1], Sohil Gala[2], Khushboo Gala[3]

Abstract

A laryngocele is an abnormal dilation of the laryngeal saccule going up into the false vocal fold that is usually air-filled and communicates with the laryngeal lumen with an incidence of about 1 in 2.5 million. These can be internal or combined laryngoceles and presentation depends on the type and size of the laryngocele. Small laryngoceles may be asymptomatic and may be incidentally detected. Management depends on the type, extent, and presentation and it ranges from close observation to surgical excision externally or microlaryngoscopically. We discuss a case of a large combined laryngocele that was managed using an external approach with complete resolution.

Keywords: Combined laryngocele, External Laryngocele, Laryngocele.

International Journal of Phonosurgery & Laryngology (2021): 10.5005/jp-journals-10023-1196

Introduction

A laryngocele is an abnormal dilation of the laryngeal saccule that extends upward within the false vocal fold, is usually air-filled, and communicates with the laryngeal lumen.[1,2]

The incidence of laryngoceles is estimated to be 1 per 2.5 million of the population per year[3] and has been reported more frequently in males, with a peak incidence in the sixth decade of life.[4]

When small, these are usually asymptomatic and incidentally discovered while imaging the neck for other indications. Symptoms vary according to the size and extension of the laryngocele and may include voice change, lump sensation, neck swelling, swallowing problems, and rarely airway compromise and stridor. Laryngoceles may get infected, forming a laryngopyocele, and may even lead to deep neck space infections.[5] Endoluminal rupture may cause aspiration pneumonia.

Laryngoceles are very uncommon entities and currently, there is no consensus regarding their surgical treatment. Various modalities of treatment have been utilized.[6,7] An external approach, the traditional treatment, is still being advocated by most authors[6,7] However, endoscopic management of laryngoceles has gained popularity during the last two decades, following the advent of microlaryngoscopic surgery and CO_2 lasers.[8–10]

The decision to treat and the modality and approach of treatment depends on the size, presentation, and radiological features and of course the surgeon's preference, expertise, and availability of equipment.

Case Description

A 65-year-old man from Saudi Arabia presented to us with hoarseness and globus sensation for 18 months. The patient was a chronic smoker, had a sedentary job profile, and had a frequent history of voice abuse. Rigid Hopkins 70° laryngoscopy revealed a left supra-glottic smooth bulge extending to the left aryepiglottic fold and left pyriform fossa, partly obscuring the left true vocal fold (Fig. 1). Bilateral true vocal folds were mobile. The patient had a maximal phonation time of 12 seconds.

Contrast high-resolution computed tomography of the neck revealed a left-sided air-filled combined laryngocele with a large external component and a small internal component causing minimal airway luminal narrowing (Fig. 2).

The patient had no visible external swelling but presented with a small left neck bulge on the Valsalva maneuver (Fig. 3).

We scheduled the patient for excision of the laryngocele using an external trans-thyrohyoid approach under general anesthesia. Transverse skin crease incision was taken at the level of hyoid and dissection was done up to the subplatysmal planes. Strap muscles were divided and exposure to the swelling was obtained (Fig. 4).

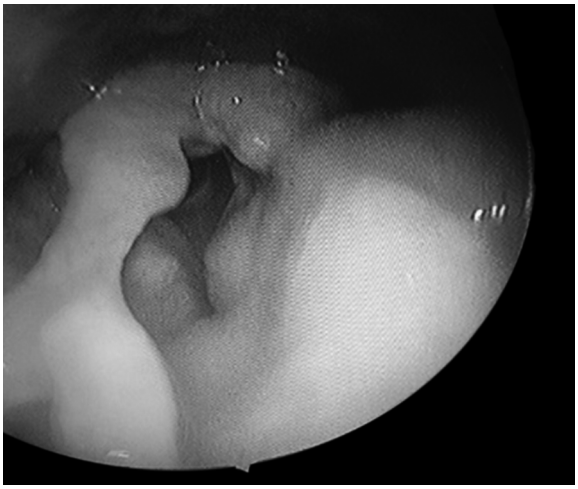

Fig. 1: Laryngoscopy shows the left supra-glottic bulge

[1–3]Department of ENT, PVT, Mumbai, Maharashtra, India

Corresponding Author: Sohil Gala, Department of ENT, PVT, Mumbai, Maharashtra, India, Phone: +91 223531018, e-mail: sohilgala17@gmail.com

How to cite this article: Gala S, Gala S, Gala K. A Rare Case of a Combined Laryngocele. Int J Phonosurg Laryngol 2021;XX(X):1–4.

Source of support: Nil

Conflict of interest: None

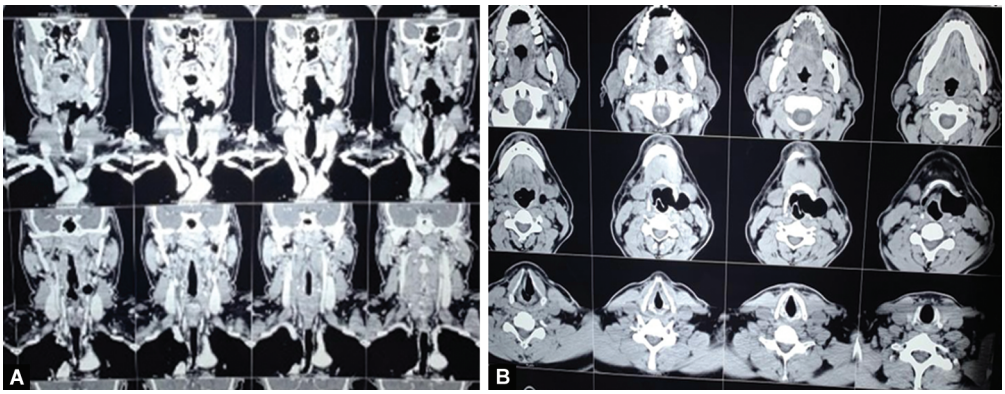

Figs 2A and B: Computed tomography shows large combined laryngocele in coronal and axial planes

Figs 3A and B: Patient has no external swelling at rest but shows a bulge in the neck on Valsalva maneuver

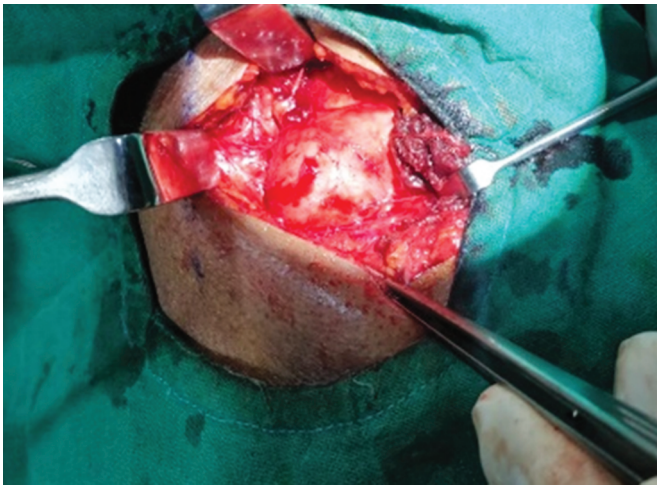

Fig. 4: Intraoperative view shows laryngocele after dividing strap muscles

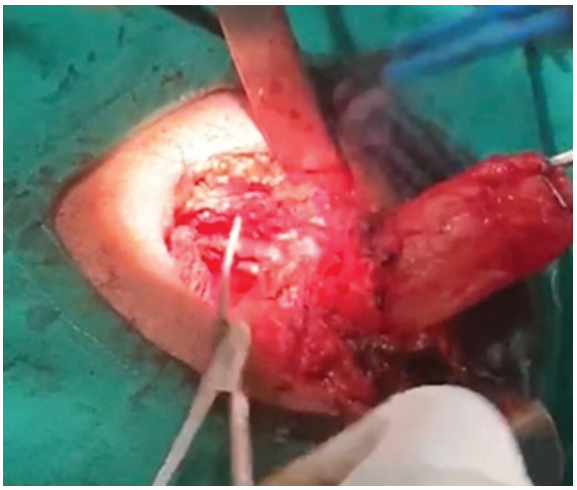

Fig. 5: Intraoperative view shows laryngocele being delivered out

Fig. 6: Laryngocele specimen excised completely

The swelling was dissected all-around reach the stalk and then gentle traction was applied to deliver the internal component as well (Fig. 5). The laryngocele was transfixed and divided and was excised in toto (Fig. 6). The 4.5 cm laryngocele thus excised was subjected to a histopathological examination which confirmed a benign swelling lined by ciliated columnar cells with lymphoid stroma with no e/o atypia or malignancy.

The patient was assessed after 5 days where the patient reported slight improvement of voice and the laryngoscopy showed resolution of the swelling (Fig. 7). The patient is nearly asymptomatic at present, is undergoing voice therapy, and is scheduled for reassessment after 3 months.

Discussion

The term laryngocele was introduced by Virchow in 1867 to describe abnormal dilatation of the saccule or ventricle.[11] These were defined

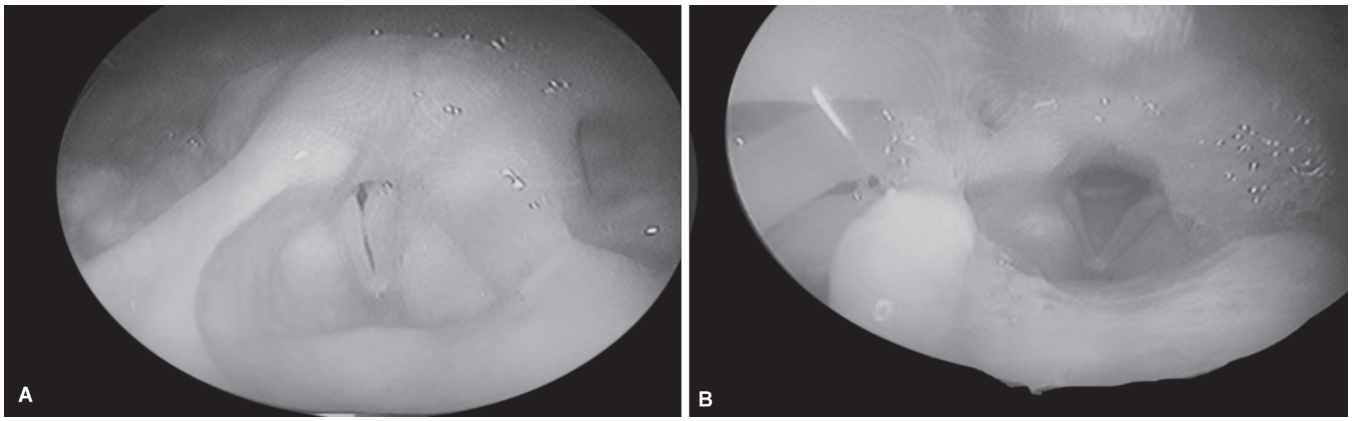

Figs 7A and B: Laryngoscopy postoperative shows complete resolution

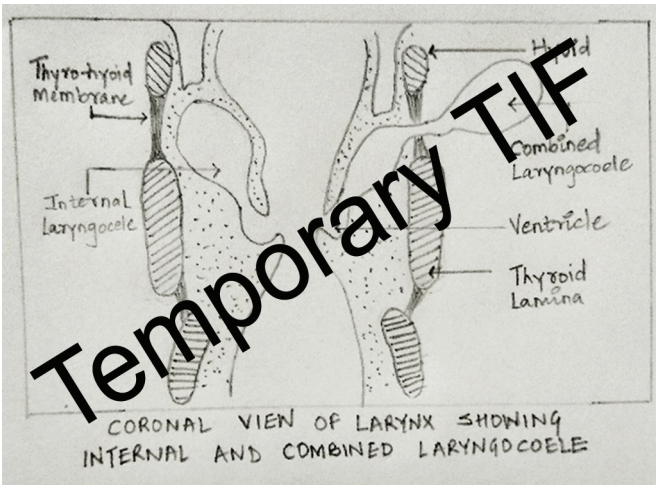

Fig. 8: Schematic representation of the types of laryngocele

by Holinger as laryngeal saccules, which were radiologically found to extend above the superior margin of the thyroid cartilage.[1]

Three main theories regarding its etiology have been proposed.[12,13]

- Congenital—Due to congenital anatomical variations, e.g., large saccules.
- Increased pressure—Individuals like glass blowers, trumpet players are more prone due to chronic increase in intraluminal laryngeal pressures leading to gradual dilatation of the saccule.[14]
- Mechanical obstruction—Mechanical obstruction of the ventricle as a result of acquired laryngeal disease (carcinoma, amyloidosis, and others) can cause increased intra-ventricular pressure and promote dilatation of the saccule.[15]

Classically laryngoceles are classified into three types as follows:[16]

- Internal laryngocele (which remain within the larynx).
- External (lateral extension through the thyrohyoid membrane).
- Mixed type.

However, this classification has been modified as now having only two types, i.e., internal and combined/mixed, as all laryngoceles originate from laryngeal saccule, therefore all will have an internal component (Fig. 8).[6]

Laryngoceles are usually filled with air till the time they retain their communication with the laryngeal lumen. They can be fluid-filled or even pus-filled (laryngopyocele) when they become isolated from the laryngeal lumen due to obstruction at the neck of the lumen. The clinical presentation can vary depending upon the anatomical location. Most of them are asymptomatic and are diagnosed when the patient is evaluated for an unrelated condition. Features of respiratory distress, foreign body sensation in the throat, and hoarseness are more common in the internal type. Patients with combined laryngocele can present with a neck mass that is soft and maybe reducible in size on palpation due to air escape into the larynx, in addition to features of internal laryngoceles.

The differential diagnosis includes saccular cyst, branchial cyst, neck abscesses, and lymphadenopathy.[17]

Essentially, laryngoceles are diagnosed clinically. Neck swelling if present is classically reducible by pressure and increases in size on Valsalva. History of voice change, with supra-glottic fullness and presence of a reducible external swelling, can be pathognomic of a combined laryngocele. USG neck is helpful to differentiate it from other neck masses. CT neck has become the initial radiographic modality of choice for evaluation. It helps to identify the type of laryngocele, distinguish the laryngoceles from other cystic neck pathologies, as they can be seen as air-filled or fluid-filled lesions in para-laryngeal space or lateral neck across the thyrohyoid membrane. It is also useful in the identification of coexisting laryngeal carcinoma or other lesions. MRI provides detailed information on the boundaries of the air/fluid-filled sac especially if there is suspicion of laryngomucocele or laryngopyocele. It also distinguishes between the obstructed mucus and inflammation from neoplastic disease.[18,19]

Laryngocele is a very rare condition, with limited literature, and presents a treatment dilemma. Many authors advocate observation in cases of asymptomatic presentations. But there have been reports of the presence of malignancy in a laryngocele and hence some recommend surgery even in asymptomatic patients, especially if there is a history of chronic smoking. Surgery is the only treatment option for symptomatic cases. Many types of surgical options have been used in its treatment. Excision of both types, combined and internal, was traditionally done using an external approach.[7] However, with the advent of microlaryngoscopic surgery and the CO_2 laser during the last two decades, the endolaryngeal technique has gained popularity and many of the authors have begun to use this technique for the treatment of internal laryngoceles.[9,10]

Moreover, some authors have begun to use a microlaryngoscopy technique for the treatment of combined laryngoceles as well.[10]

The reported advantages of external approaches are good exposure of the laryngocele, a more precise procedure, and a low recurrence rate. Disadvantages are skin scarring, higher morbidity, longer duration of surgery, longer hospitalization period, and higher costs.[6]

On the other hand, the endolaryngeal management of laryngoceles has the disadvantages of providing limited surgical exposure, causing endolaryngeal scarring, and requiring experience with special instruments. Furthermore, the probability of incomplete resection of large laryngoceles limits the use of the endoscopic approach.[6]

Three types of external procedures have been used during the past 20 years—the transthyrohyoid membrane approach, thyrotomy with resection of the upper 1/3 of the thyroid cartilage, and V-shaped thyrotomy.[7]

Laryngocele may rarely present as an acute airway obstruction warranting a tracheostomy on certain occasions. Elective tracheostomy may have to be considered in certain cases where endolaryngeal intubation is difficult at the time of surgery.

One must always keep in mind the potential outcomes like laryngo-cutaneous fistula, surgical emphysema, and a chance of damage to pyriform sinus mucosa during a surgical excision, and must be prepared to tackle these complications.

Our patient had slight voice change and foreign body sensation throat as his presenting complaint and no external swelling at rest. We decided to excise the swelling in view of the large size radiologically, and history of chronic smoking keeping in mind a very rare possibility of malignant transformation. We decided to go ahead with an external transthyrohyoid membrane approach since it had a large external and a very small internal component. We were aiming at complete excision with a low recurrence chance as the patient had doubtful follow-up history. We could successfully excise the lesion completely with good exposure with no complications, as advocated by most reports in the literature.

Conclusion

A high index of suspicion in atypical laryngeal lesions and a thorough clinical and radiological assessment is a must for adequate and ideal management of such cases. A thorough review of literature and discussion with peers helped us manage this rare case of laryngocele adequately with no complications.

References

1. Holinger LD, Barnes DR, Smid LJ, et al. Laryngocoele and saccular cysts. Ann Otol, Rhinol Laryngol 1978;87(no. 5 part 1):675–685. DOI: 10.1177/000348947808700513.
2. DeSanto LW. Laryngocele, laryngeal mucocele, large saccules, and laryngeal saccular cysts: a developmental spectrum. Laryngoscope 1974;84(no. 8):1291–1296. DOI: 10.1288/00005537-197408000-00003.
3. Stell PM, Maran AGD. Laryngocele. J Laryngol Otol 1975;89(9):915–924. DOI: 10.1017/s0022215100081196.
4. Ingrams D, Hein D, Marks N. Laryngocele: an anatomical variant. J Laryngol Otol 1999;113(no. 7):675–677. DOI: 10.1017/s0022215100144822.
5. Al-Yahya SN, Baki MM, Saad SM, et al. Laryngopyocele: report of a rare case and systematic review. Ann Saudi Med 2016;36(4):292–297. DOI: 10.5144/0256-4947.2016.292.
6. Thome R, Thomé DC, De La Cortina RAC. Lateral thyrotomy approach on the paraglottic space for laryngocele resection. Laryngoscope 2000;110(no. 3, part 1):447–450. DOI: 10.1097/00005537-200003000-00023.
7. Myssiorek D, Madnani D, Delacure MD. The external approach for submucosal lesions of the larynx. Otolaryngol Head Neck Surg 2001;125(no. 4):370–373. DOI: 10.1067/mhn.2001.118690.
8. Szwarc BJ, Kashima HK. Endoscopic management of a combined laryngocele. Ann Otol, Rhinol Laryngol 1997;106(no. 7, part 1):556–559. DOI: 10.1177/000348949710600704.
9. Dursun G, Ozgursoy OB, Beton S, et al. Current diagnosis and treatment of laryngocele in adults. Otolaryngol Head Neck Surg 2007;136(no. 2):211–215. DOI: 10.1016/j.otohns.2006.09.008.
10. Devesa PM, Ghufoor K, Lloyd S, et al. Endoscopic CO_2 laser management of laryngocele. Laryngoscope 2002;112(no. 8, part 1):1426–1430. DOI: 10.1097/00005537-200208000-00018.
11. Virchow R. Die Krankhaften Geschwulste. Berlin: Hirschwald; 1963. pp. 35–40.
12. Amin M, Maran AG. The aetiology of laryngocoele. Clin Otolaryngol 1988;13(4):267–272. DOI: 10.1111/j.1365-2273.1988.tb01130.x.
13. Canalis RF, Maxwell DS, Hemenway WG. Laryngocele--an updated review. J Otolaryngol 1977;6(3):191–199.
14. Macfie DD. Asymptomatic laryngoceles in wind instrument bandsmen. Arch Otolaryngol 1966;83(3):270–275. DOI: 10.1001/archotol.1966.00760020272018.
15. Celin SE, Johnson J, Curtin H, et al. The association of laryngoceles with squamous cell carcinoma of the larynx. Laryngoscope 1991;101(5):529–536. DOI: 10.1288/00005537-199105000-00016.
16. Cassano L, Lombardo P, Ragona RM, et al. Laryngopyocele: three new clinical cases and review of the literature. Eur Arch Oto-Rhino Laryngol 2000;257(9):507–511. DOI: 10.1007/s004050000274.
17. Keles E, Alpay HC, Orhan I, et al. Combined laryngocele: a cause of stridor and cervical swelling. Auris Nasus Larynx 2010;37(1):117–120. DOI: 10.1016/j.anl.2009.02.011.
18. Parsons CA, Chapman P, Counter RT, et al. The role of computed tomography in tumours of the larynx. Clin Rad 1980;31(5):529–533. DOI: 10.1016/s0009-9260(80)80038-9.
19. Dwivedi G, Gupta V, Singh I, et al. Rare case of combined laryngocoele masquerading as laryngeal carcinoma: a case report and review of literature. Int J Otorhinolaryng Head Neck Surg 2018;4(1):292–296. DOI: 10.18203/issn.2454-5929.ijohns20175646.