

CASE REPORT

Pleomorphic Adenoma of Hard Palate: A Case Series

Seema R Gupta¹, Vandana P Thorawade², Mohammad Hanif MS Khan³

ABSTRACT

Introduction: Pleomorphic adenoma of minor salivary glands of the hard palate is a rare benign tumor that has elements of both epithelial and mesenchymal tissues. It usually presents as slow-growing painless submucosal mass on the hard palate. Diagnosis rests on clinical features and tissue examination with radiological investigations helping in surgical planning.

Aim: To add to the literature few more cases of this relatively rare condition and discuss its clinical presentation and management.

Case description: Here, we present a case series of three patients who presented with a mass over the hard palate that was subsequently diagnosed as pleomorphic adenoma and discuss the treatment of the same.

Conclusion: Treatment of choice is wide local excision with removal of periosteum or bone if involved. Recurrence rate is low.

Keywords: Hard palate, Pleomorphic adenoma, Salivary gland.

Otorhinolaryngology Clinics: An International Journal (2020): 10.5005/jp-journals-10003-1305

INTRODUCTION

Salivary gland tumors form <3% of the head and neck tumors.¹ Being the most common salivary gland tumor, pleomorphic adenoma accounts for about 60% of all major and minor salivary gland tumors.² Among the minor salivary glands tumors, 70% are pleomorphic adenomas and the most common site in the oral cavity is the palatal area, followed by the lip, buccal mucosa, floor of mouth, tongue, tonsil, pharynx, retromolar trigone, and gingiva. Females are commonly affected.³ Pleomorphic adenoma of the hard palate presents as a painless firm submucosal mass without tenderness, ulceration, or surrounding inflammation; usually, they lack a well-defined capsule and frequently involve periosteum or bone.³ Due to the distribution and arrangement of minor salivary tissues of the palate, these tumors are located laterally and rarely cross the midline.⁴

CASE REPORT

- A 17-year-old female patient presented to our outpatient department with complaint of swelling over the palate for 5 months. The swelling was growing slowly. There was no h/o pain or preceding trauma and no relevant past history. Intraoral examination revealed a 5 × 5 × 4 cm³ well-defined swelling with intact overlying mucosa over the left side of the anterior hard palate. The swelling was non-tender, firm, and non-mobile. There was no regional lymphadenopathy, and general and systemic examinations were normal. Fine needle aspiration cytology (FNAC) and computerized tomography (CT) scan were done. FNAC report came as pleomorphic adenoma, while CT scan suggested a 4.9 × 4.7 × 3.2 cm³ lesion over the left side of the hard palate without any periosteum or bone invasion, most probably being benign neoplastic lesion.
- A 25-year-old man came to our outpatient department complaining of a painless swelling over the palate for 6 months. On examination, a 5 × 4 × 4 cm³ non-tender, firm swelling was present on the right side of the hard palate with intact overlying mucosa (Fig. 1). Right submandibular lymphadenopathy was noted with systemic and general examinations being normal.

¹⁻³Department of ENT, Dr. Vaishampayan Memorial Government Medical College, Solapur, Maharashtra, India

Corresponding Author: Seema R Gupta, Department of ENT, Dr. Vaishampayan Memorial Government Medical College, Solapur, Maharashtra, India, Phone: +91 9372575309, e-mail: mailmeseema.gupta5@gmail.com

How to cite this article: Gupta SR, Thorawade VP, Khan MHMS. Pleomorphic Adenoma of Hard Palate: A Case Series. *Int J Otorhinolaryngol Clin* 2020;12(1):xx-xx.

Source of support: Nil

Conflict of interest: None

FNAC was done, which was suggestive of pleomorphic adenoma, while CT scan showed it to be a benign neoplastic lesion over the right side of the hard palate without invasion of periosteum or bone.

- A 40-year-old female patient came to us with a slow-growing swelling over the palate for the past 9 months. A 4 × 4 × 3 cm³ non-tender, soft to firm swelling was seen on the left side of the hard palate with normal overlying mucosa. FNAC and CT scan showed it to be a pleomorphic adenoma without the involvement of the underlying bone.

All these patients were treated by wide local excision without curettage of bone under general anesthesia (Figs 2 and 3). The specimen was sent for histopathological examination, which confirmed the diagnosis of pleomorphic adenoma. The postoperative period was uneventful. After 6 months of follow-up after operation, none of them showed any recurrence.

DISCUSSION

These tumors originate from intercalated and myoepithelial cells and contain both epithelial and mesenchymal tissues. Epithelial elements may be arranged in duct-like structure, sheets, clumps, or interlacing strands, and the stroma may be mucoid, myxoid, cartilaginous, or hyaline surrounded by a fibrous pseudocapsule.⁵

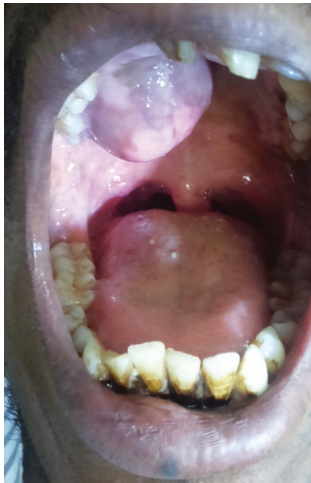

Fig. 1: Oral cavity examination showing swelling over right side of the hard palate

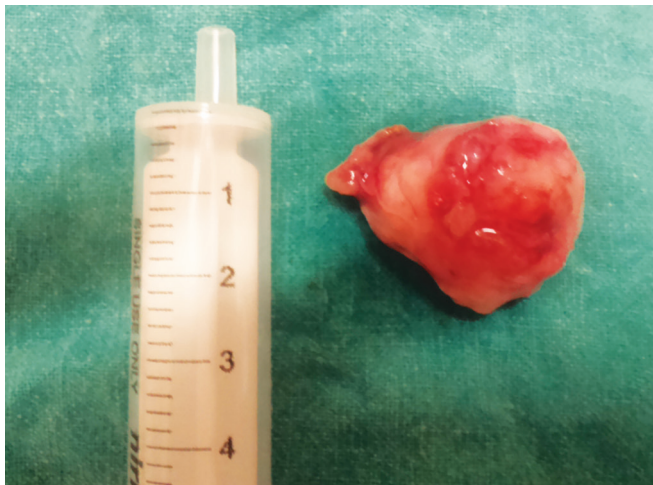

Fig. 2: Surgical pathology specimen after removal

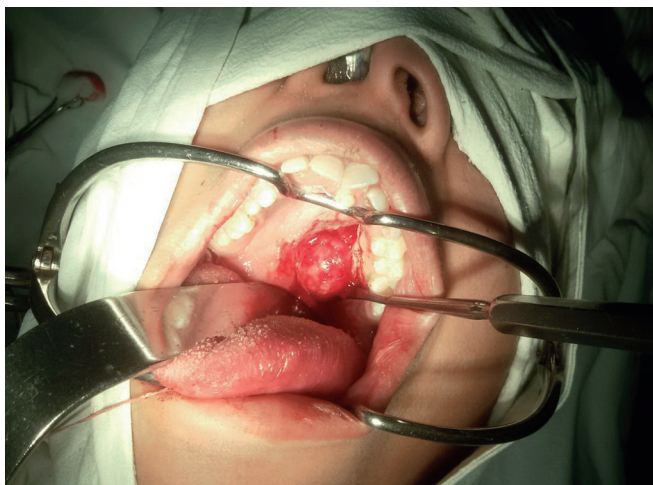


Fig. 3: Excision being performed

Based on the proportion of epithelial and stromal components, Seifert et al. classified the tumor into four types. Type I comprised of principally myxoid variant, type II comprised of myxoid and cellular variants, type III comprised of predominantly cellular variant, and type IV comprised of an extremely cellular variant.⁴ Minor salivary gland pleomorphic adenoma is in general more cellular in nature.⁴ The tumor has been linked with clonal chromosome abnormalities with aberrations involving 8q12 and 12q15.⁵

Differential diagnosis of pleomorphic adenoma includes odontogenic and non-odontogenic cysts, palatal abscess, mucoepidermoid carcinoma, adenoid cystic carcinoma, rhabdomyosarcoma, lymphoma, and soft tissue tumors, such as, neurofibroma, fibroma, lipoma, and neurilemmoma.^{3,5}

Pleomorphic adenoma is diagnosed on the basis of history, physical examination, cytology (FNAC), and histopathology. Computed tomography scan and magnetic resonance imaging aid to know the location, size, and extension of tumor to the surrounding superficial and deep structures. Core needle biopsy has higher diagnostic accuracy (greater than 97%) as compared to FNAC.³

The hard palate pleomorphic adenoma is treated by wide local excision with the removal of periosteum or bone if they are involved. Wide local excision involves removing the tumor along with a surrounding cuff of normal tissue as the tumor lacks a well-defined capsule and has pseudopods present.⁶ Reconstruction is required if there is full thickness defect in the bone and is done by obturator or palatal flap based on greater palatine vessels.³ Soft tissue defect can be allowed to granulate and heal by itself. Reconstruction is needed for the maintenance of speech, swallowing, and anterior facial projection.⁵ According to Spiro, pleomorphic adenoma has a recurrence rate of 6%⁷ and most recurrences are due to inadequate surgical techniques such as simple enucleation leaving behind microscopic pseudopod-like extensions, capsular penetration, and tumor rupture with spillage of tumor cells. Hence, simple enucleation should be avoided.³ The recurrent tumors are often multinodular and lack surrounding capsule, making their surgical excision difficult.⁴ The malignant potential of pleomorphic adenoma is about 6%.⁵

CONCLUSION

Pleomorphic adenoma of the hard palate is a relatively rare tumor whose diagnosis depends on clinical features and cytology and histopathology reports. Treatment includes wide local excision, and simple enucleation should be avoided as it leads to recurrence. Recurrence rate is low with wide local excision, and hence, it is the treatment of choice.

REFERENCES

1. Luna MA, Batsakis JG, El-Naggar AK. Salivary gland tumors in children. *Ann Otol Rhinol Laryngol* 1991;100:869–871. DOI: 10.1177/000348949110001016.
2. Pinkston JA, Cole P. Incidence rates of salivary gland tumors: results from a population based study. *Otolaryngol Head Neck Surg* 1999;120(6):834–840. DOI: 10.1016/S0194-5998(99)70323-2.
3. Patigaroo SA, Patigaroo FA, Ashraf J, et al. Pleomorphic adenoma of hard palate: an experience. *J Maxillofac Oral Surg* 2014 Mar;13(1):36–41. DOI: 10.1007/s12663-012-0448-5.
4. Satpathy Y, Spadigam AE, Dhupar A, et al. Epithelial and stromal patterns of pleomorphic adenoma of minor salivary glands: a

- histopathological and histochemical study. *J Oral Maxillofac Pathol* 2014 Sep–Dec;18(3):379–385. DOI: 10.4103/0973-029X.151319.
5. Rahmana M, Orzedala-Koszel U, Czupkalo L, et al. Pleomorphic adenoma of the palate: a case report and review of the literature. *Contemp Oncol (Pozn)* 2013;17(1):103–106. DOI: 10.5114/wo.2013.33438.
 6. De Courten A, Lombardi T, Samson J. Pleomorphic adenoma in a child: 9-year follow-up. *Int J Oral Maxillofac Surg* 1996;25:293–295. DOI: 10.1016/S0901-5027(06)80060-3.
 7. Spiro RH. Salivary neoplasms: overview of a 35 year experience with 2807 patients. *Head Neck Surg* 1986;8(3):177–184. DOI: 10.1002/hed.2890080309.