

Endonasal Endoscopic Excision of Sinonasal Malignancies: An Overview

Pookamala Sathasivam

Received on: 26 March 2021; Accepted on: 06 June 2023; Published on: xx xxxx xxxx

ABSTRACT

Sinonasal malignancies are relatively an uncommon entity and squamous cell carcinoma is the commonest malignancy. Tumor mainly arises from the mucosa of nasal cavity or maxillary sinus. Primary tumor from the frontal and sphenoid sinuses are very rare. Patients often present with advanced disease, as the initial symptoms of tumor, such as nasal block, nasal bleeding, and nasal discharge mimic those of common nasal pathology such as rhinitis/sinusitis. The ideal treatment for sinonasal malignancy is surgery, followed by postoperative radiotherapy. Traditionally, such tumors were treated with open surgical excision or combined craniofacial resection in the case of skull base involvement. Now in the era of minimally invasive surgery, more and more such tumors are diagnosed early and operated on via a transnasal endoscopic approach. This article will serve as a guide for surgeons planning to operate upon such tumors endoscopically.

Keywords: CSF leak, CSF leak repair, Endoscopic endonasal, Endoscopic excision, Endoscopic nasal surgeries, Endonasal transsphenoidal approach, Sinonasal malignancy, Squamous cell carcinoma.

Clinical Rhinology (2020); 10.5005/jp-journals-10013-1385

INTRODUCTION

Malignancies of the nose and paranasal sinuses (PNS) are relatively rare and they constitute less than 1% of all malignancies.¹ Squamous cell carcinoma is the most common sinonasal malignancy.² Other common sinonasal malignancies include adenocarcinoma, adenoid cystic carcinoma, chondrosarcoma, esthesioneuroblastoma, rhabdomyosarcoma, angiosarcoma, hemangiopericytoma, and malignant melanoma. The clinical symptoms of sinonasal malignancy includes nasal blockage, nasal bleeding, headache, vision/smell disturbance, and facial swelling. Tumor usually arises from the nasal or septal mucosa and tend to spread easily to nearby vital structures by eroding the underlying bone.¹ In ethmoid malignancy, papery thin bone of ethmoid sinus offers very minimal resistance, and hence tumor can spread readily into orbit and anterior cranial fossa. Also these tumors can spread readily into difficult access areas such as infratemporal fossa, pterygopalatine fossa, anterior and middle skull base via neural foramina or bony fissures. Hence, most of the patients present with advanced disease at the time of diagnosis.³ All these factors make treatment aspect more challenging and they have an impact on treatment outcome. Traditionally, sinonasal malignancies were treated by open radical surgery followed by radiotherapy when the lesion seems operable⁴ and for tumors with intracranial extension, combined transcranial excision is done. Now in the era of minimally invasive surgery, more and more such tumors are being operated endoscopically. Currently, endoscope has replaced traditional headlight and mirror examination in ENT clinics, so most of the tumors are diagnosed at a very early stage itself. Modern ENT surgeons are more experienced in endoscopic surgery than open approach excision. Hence, the concept of endoscopic excision of sinonasal malignancy has become more relevant now. The purpose of this article is to summarize the role of endoscopic surgery in managing malignant lesions of the nose and paranasal sinuses (PNS) without compromising oncologic principles.

Department of ENT, AIIMS, Madurai, Tamil Nadu, India

Corresponding Author: Pookamala Sathasivam, Department of ENT, AIIMS, Madurai, Tamil Nadu, India, Phone: +91 9791021936, e-mail: pookamala@yahoo.com

How to cite this article: Sathasivam P. Endonasal Endoscopic Excision of Sinonasal Malignancies: An Overview. *Clin Rhinol* 2020;xx(x):xx-xx.

Source of support: Nil

Conflict of interest: None

EPIDEMIOLOGY

Sinonasal malignancy commonly affects males in the age-group of 40–69 years.⁵ Etiological factors for sinonasal malignancy includes smoking, wood dust, tannins, and other solvents from leather industry.⁶ Squamous cell carcinoma is the most common sinonasal malignancy followed by adenocarcinoma and they both constitute 80% of all sinonasal malignancy. Sinonasal adenocarcinoma (ITAC – Intestinal type adenocarcinoma) is commonly reported in wood workers and those working in leather factory.⁷ Common sites of origin of sinonasal malignancy includes nasal cavity and maxillary sinus. Most of the patients present with advanced local disease without any evidence of nodal or distant metastasis.⁸ Proper treatment planning is essential for the management of sinonasal malignancy in view of complex anatomy, proximity to vital structures, and varied histopathology.

PREOPERATIVE INVESTIGATIONS

Adequate preoperative evaluation is essential to arrive at diagnosis and to help in disease staging and treatment planning. Imaging of the nose and PNS is to be done in any patient with nasal mass lesion for proper treatment planning. Contrast-enhanced CT scan of PNS is the initial imaging of choice. It gives valuable information such as origin/extent of disease, extent of bony erosion, orbit and

skull base involvement, intracranial extension, tumor vascularity etc.⁹ CT angiography may be required to assess the feeder if the tumor appears highly vascular on contrast-enhanced CT. A separate CT scan with image guidance protocol needs to be done if intraoperative image guidance is planned during surgery. CT scan must always be complemented by MRI of PNS when evaluating a malignant lesion.

Malignant tumors usually exhibit nonspecific hyperintensity on T2-weighted images (T2WI) and hypo- to isointensity on T1-weighted images (T1WI) except malignant melanoma which is hyperintense on T1WI.¹⁰ On T1WI, hyperintensity within a tumor is indicative of the presence of methemoglobin, melanin, lipid, protein, and mineral elements. T2-weighted MRI helps to differentiate between tumor tissue and retained secretions within paranasal sinuses. Retained secretions appear hyperintense on T2WI in MRI, whereas a tumor does not appear so. Diffusion-weighted image (DWI) with the measurement of apparent diffusion coefficient (ADC) captures the degree of Brownian movement of the water molecules in tissues and it serves as a useful imaging biomarker. Low-ADC lesions with strong diffusion restriction indicates hypercellularity, abscess, or hemorrhage, whereas high-ADC lesions indicate hypocellularity, mucus, cartilage, or fluid. Therefore, DWI with ADC measurement is very useful to differentiate between benign and malignant tumors.¹ The ADC of malignant tumor is very low ($0.87 \pm 0.32 \times 10^{-3} \text{ mm}^2/\text{s}$) compared with benign tumors ($1.35 \pm 0.29 \times 10^{-3} \text{ mm}^2/\text{s}$).¹¹ Tumor extent in intracranial cavity, infratemporal fossa, pterygopalatine fossa, skull base and cavernous sinus area is better delineated on MRI than CT. In tumors like adenoid cystic carcinoma which has potential for peri-neural spread, MRI helps in predicting neural involvement of the commonly involved nerves like maxillary and vidian nerve.¹ MRI features of specific tumors are summarized in Table 1.

Endoscopic biopsy of the lesion must be done prior to surgery. Biopsy can be done in outpatient setting if the tumor does not appear vascular on imaging.¹² When biopsy is performed in outpatient setup, topical anesthesia is achieved by using cottonoids soaked with a mixture of 4% xylocaine and adrenaline solution (mix of 30 mL of 4% xylocaine and 1 mL of adrenaline 1:1000).¹³ However,

for deep-seated lesions with increased vascularity biopsy must be done in operation theatre setting with facility for cauterization and nasal packing. During biopsy, adequate viable tissue must be sampled without causing forceps-induced crush artifacts as certain nasal malignancy harbors extensive necrotic tissue which can interfere with histopathology reporting if proper sampling is not done. Immunohistochemistry of the biopsy sample may be required in certain situations to arrive at diagnosis.

Fine needle aspiration biopsy (FNAB) of the lesion (either direct or CT-guided) can also be tried when the lesion is seen involving cheek, palate, orbit, and for retropharyngeal nodes.¹⁴ For metastatic workup, other investigations, such as CT chest, USG of abdomen, 18FDG PET scan may be required on case to case basis.

TREATMENT PLANNING AND GUIDELINES

In any nasal and paranasal malignancy other than lymphomas, the ideal treatment option is surgery followed by adjuvant RT/CTRT provided the tumor is operable.⁹ After initial diagnostic workup and disease staging, patient is discussed in head and neck tumor board in the presence of medical, radiation oncologist, and ENT surgeon (for tumor staging refer Table 2). Other specialists, such

Table 1: MRI features of sinonasal tumors

<i>Tumor type/features</i>	<i>MRI features</i>
Inverted papilloma	Cerebriform appearance on T2WI or T1WI with contrast (striated appearance) ³⁴
Olfactory neuroblastoma	Peritumoral cyst formation along the intracranial portion of tumor ³⁵
Malignant melanoma	Hyperintensity on T1WI
Adenoid cystic carcinoma	Perineural enhancement
Perineural spread	Nerve thickening with enhancement, widening of neural foramina, loss of perineural fat ¹
Dural invasion	Dural thickening > 5 mm, pial enhancement, focal nodules in dura ¹

Table 2: AJCC staging of sinonasal malignancy³⁶

<i>Staging of maxillary malignancy</i>	<i>Tumor extension</i>
T1	Tumor limited to the mucosa with no erosion or destruction of bone
T2	Tumor causing bone erosion or destruction, including extension into hard palate and/or middle nasal meatus, except extension to posterior wall of maxillary sinus and pterygoid plates
T3	Tumor invades any of the following: bone of posterior wall of maxillary sinus, subcutaneous tissues, floor or medial wall of orbit, pterygoid fossa, ethmoid sinuses
T4a	Tumor invades any of the following: anterior orbital contents, skin of cheek, pterygoid plates, infratemporal fossa, cribriform plate, sphenoid or frontal sinuses
T4b	Tumor invades any of the following: orbital apex, dura, brain, middle cranial fossa, cranial nerves other than maxillary division of trigeminal nerve V2, nasopharynx, clivus
<i>Nasal cavity and ethmoid sinus</i>	
T1	Tumor restricted to one subsite of nasal cavity or ethmoid sinus, with or without bony invasion
T2	Tumor involves two subsites in a single site or extends to involve an adjacent site within the nasoethmoidal complex, with or without bony invasion
T3	Tumor extends to invade the medial wall or floor of the orbit, maxillary sinus, palate or cribriform plate
T4a	Tumor invades any of the following: anterior orbital contents, skin of nose or cheek, minimal extension to anterior cranial fossa, pterygoid plates, sphenoid or frontal sinuses
T4b	Tumor invades any of the following: orbital apex, dura, brain, middle cranial fossa, cranial nerves other than V2, nasopharynx, clivus

as radiologist, pathologist, neurosurgeon, prosthodontist, speech and swallow therapist are also involved in the treatment planning when necessary. Once patient is planned for surgery, surgical planning is done on various aspects, such as surgical approach (open/endoscopic/combined), need for flap cover (nasoseptal, pericranial, temporoparietal, free flap) prosthetic requirements (palatal obturator), frozen section biopsy, neurosurgical back up, ICU requirement, and blood reservation. Preadmission consultation is done prior to surgery. During anesthetic consultation issues, such as need for hypotensive anesthesia, tumor vascularity, intracranial spread of tumor, risk of CSF leak and duration of surgery must be discussed.

Guidelines for sinonasal malignancy management includes:⁹

- Treatment of sinonasal malignancy should be carefully planned and discussed at a specialist skull base multidisciplinary team meeting with all relevant expertise.
- The most common management approach is surgery followed by postoperative radiotherapy, ideally within 6 weeks.
- To ensure the optimum oncological results, the primary tumor must be completely removed and margins checked by frozen section if necessary.
- Essential equipment is necessary and must be available prior to commencing endonasal resection of skull base malignancy.
- Endoscopic skull base surgery may be facilitated by two surgeons working simultaneously, utilizing both sides of the nose.

SURGICAL INSTRUMENTS

In addition, the standard FESS instruments as additional instruments are required for complete tumor excision. Devices such as microdebrider and coblation probe help in tumor debulking. Endoscopic drill system is required to drill thick bone of sphenoid, frontal recess, pterygoid area, and also to drill the bony base after tumor excision. Endoscopic vascular clip applicator and microear instrument, such as Rosen's knife, flap elevator, and bone curette are also required routinely. Other elite devices, such as image guidance system, endo-Doppler probe provide added advantage to the surgeon when operating near critical structures and carotid artery.⁹

GENERAL PRINCIPLES OF ENDOSCOPIC EXCISION OF NASAL MALIGNANCY

The endoscopic approach allows en-bloc resection of small tumors only and larger tumors are resected in piecemeal fashion and this has no influence on the prognostic outcome.¹⁵ It is essential to maintain the dissection of the neoplasm in the subperiosteal plane and to use a centripetal technique, starting at the periphery and moving toward the center.¹⁵ Adequate mucosal margins must be cleared all around the tumor and frozen section biopsy of the margins must be used whenever necessary. Endoscopic resection is aided by having two surgeons using 3 or 4 hand technique on both sides of the nose.⁹ Availability of the neurosurgeon and neuronavigation must be ensured for tumors encroaching upon the skull base area.

SURGICAL TECHNIQUE

The technical advancement of endoscopic surgery has made a major impact on the management of patients with lesions involving PNS and anterior cranial fossa. Surgery is done under general anesthesia via oral intubation. A throat pack is to be kept in

oropharynx to prevent blood trickling down from the nasopharynx region. Head end of the patient is to be kept elevated to minimize bleeding. Thigh area is prepared and draped to harvest fat and fascia at the later stage of surgery (if required). Nasal preparation is done using adrenaline-soaked cottonoids (1:5000) and infiltration of saline adrenaline solution (1:1,00,000). Hypotensive anesthesia is preferable throughout the procedure.

Tumor tissue in the nasal cavity is initially debulked using microdebrider. Coblation can also be used for this purpose to get a bloodless field. Once the tumor is debulked, effort must be made to ascertain the area of tumor attachment. In cases of nasal malignancy and inverted papilloma with malignant transformation, the most common sites of tumor attachment include nasal septum and lateral nasal wall behind the maxillary antrum. Many a times, all these tumors have a narrow attachment at one point and the rest of the lesion seen is the nasal cavity which is just an exophytic mass arising from that single attachment. Such information on the exact site of tumor attachment can only be gained from the endoscopic excision (Fig. 1). Once the site of attachment is localized, it is advisable to take samples from the mucosal margins all around the attachment to ensure adequate oncologic clearance. After that the tumor attachment is released from the base. If the attachment is over nasal septum, then that part of septum is excised with adequate margins. If the attachment is over lateral nasal wall, then the underlying bone is removed, and the nearby area is drilled using endoscopic drill.

If the tumor attachment is seen at the lateral nasal wall or medial wall of maxilla, then an endoscopic medial maxillectomy is done. Further disease clearance is done based on intraoperative assessment. If tumor attachment is seen over nasal septum with the invasion of vomer bone, then posterior septectomy and wide sphenoid antrostomy are done. The rostrum of the sphenoid and the adjoining sphenoid bone are drilled completely.

In the case of esthesioneuroblastoma or ethmoidal malignancy, anterior and posterior ethmoidectomy is done after debulking the tumor. Sphenoid osteum is identified and widened. Any tumor tissue in the sphenoid is removed and the adjoining bone is drilled out. Anteriorly, frontal recess is cleared of the disease by using Draf III approach. Laterally, lamina papyracea of orbit is removed if involved by the tumor. In the case of cribriform plate involvement, endoscopic craniofacial resection is done by removing the entire cribriform plate from the frontal recess (ant) to planum sphenoidale (post) and between two lamina on the lateral aspect.^{16,17} Many a times, the dura of the anterior cranial fossa is uninvolvement by the tumor and the tumor is mainly extradural. In patients with dural involvement, the resection includes dura along with the olfactory bulb and olfactory tract.^{17,18} However, when there is significant dural involvement, then a combined craniofacial resection with the help of a neurosurgeon is warranted.

When tumor extension is seen into pterygopalatine fossa and infratemporal fossa, then endoscopic transpterygoid approach is recommended.¹⁹ In transpterygoid approach, wide maxillary antrostomy is done to visualize the entire posterior wall of maxilla. The sphenopalatine foramen with the sphenopalatine artery is identified and cauterized. Further, mucosal dissection posteriorly exposes the orbital and sphenoidal process of palatine bone and the same is drilled completely. Superiorly vidian canal with vidian nerve and artery is identified and cauterized. Posterior wall of the maxilla is removed completely. Now, periosteum over pterygopalatine fossa and infratemporal fossa is visualized. Terminal branches of internal maxillary artery is exposed after incising the periosteum and its branches are ligated. Vidian nerve is followed

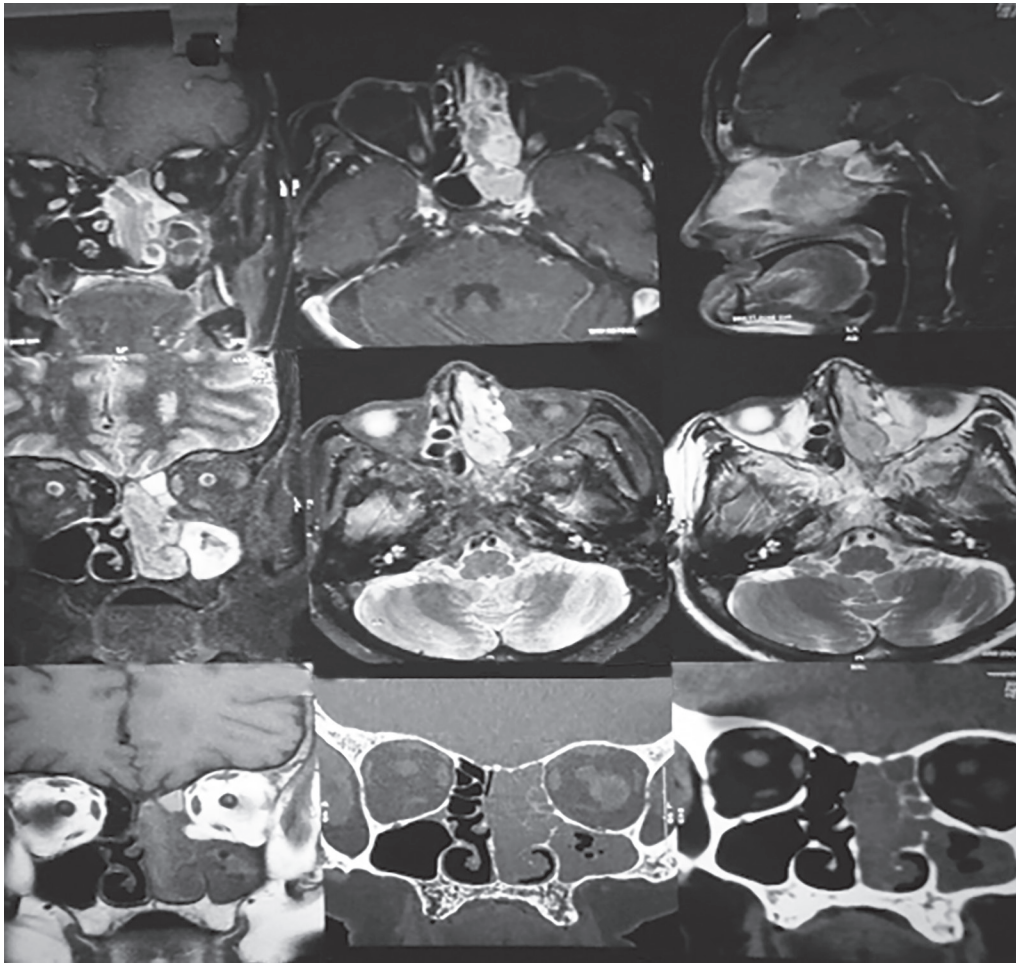


Fig 1: MRI and CT scan of a patient with sinonasal malignant melanoma. On imaging, the tumor appeared to be filling the entire nasal cavity on the left side with retained secretions in paranasal sinuses. During surgery, the tumor had a small narrow attachment at posterior end of septum which could be resected endoscopically easily with adequate margins

down to expose pterygopalatine ganglion and V2 is exposed further laterally. Further, dissection and disease clearance is based on disease extension.

CSF leak is not uncommon during such radical dissections. Local flaps can be used to treat such CSF leaks and also to cover the defect in skull base. Hadad flap based on septal branch of the sphenopalatine artery is the commonly used flap for reconstruction.²⁰ If the flap is not available due to oncologic concerns, then the pericranial flap (based supratrochlear artery) or temporoparietal flap can be transposed into to nasal cavity to cover the defect. In the case of posteriorly located tumor, with extension into sphenoid, pterygopalatine fossa and nasopharynx complete endoscopic resection is possible in selected cases only.

SKULL BASE RECONSTRUCTION AFTER ENDOSCOPIC TUMOR SURGERY²¹

Various reconstruction options are available to treat skull base defect after tumor excision. It includes local flaps, regional flaps, free flaps, and free grafts (summarized in Table 3). The choice of flap cover depends on various factors and it includes the presence/absence of CSF leak, nature of leak (high-flow/low-flow) and size/location of defect. The skull base defect closure involves

Table 3: Reconstruction options after endonasal skull base tumor excision

<i>Local flaps</i>	<i>Regional flaps</i>	<i>Free flaps</i>
Nasoseptal flap	Pericranial flap	Anterolateral thigh flap
Middle turbinate flap (MTF)	Temporoparietal flap	Radial forearm flap
Inferior turbinate flap (ITF)		
<i>Site of defect</i>	<i>Flap options</i>	
Flap selection based on location of defect		
Cribriform plate (small defect)	MTF	
Planum (small defect)	MTF	
Upper 1/3 clivus (small defect)	ITF	
Median defect	Pericranial flap	
Paramedian defect	Temporoparietal flap	

multilayered reconstruction and every layer that is opened must be reconstructed. For arachnoid defect, Inlay collagen implant is

preferred, and for dural defect, vascularized pedicle flap is used for reconstruction. Finally, only fat graft is placed over vascularized pedicle flap which acts as a biological dressing and lumbar drain is kept for all high-flow leaks.

Among all the flaps, nasoseptal flap based on septal branch of sphenopalatine artery is considered the workhorse for skull base defect reconstruction after endoscopic skull base surgery. Ideally, flap harvesting must be done at the beginning of the surgery. Simple steps like partial middle turbinectomy and outfracturing of inferior turbinated improves the visualization and surgical access. Harvested flap must be kept safely inside the nasopharynx or maxillary antrum till the completion of resection. When nasoseptal flap is not available due to oncologic reasons, then other local or regional flaps are used.

ADVANTAGES OF ENDOSCOPIC EXCISION

Tumor attachment site is seen easily during endoscopic dissection, thus it avoids unnecessary bony removal compared with conventional open approach. Most of the tumor bulk seen on preoperative imaging is in fact just an exophytic component of the tumor with a single narrow attachment. Many a times, tumor which appeared to be reaching skull base or seen close to critical vital structures in imaging is just an exophytic mass filling that space than an infiltrative lesion. Endoscopic approach is the only modality which gives such valuable information (Fig. 2). Such a finding downstages the tumor staging. Excellent magnification

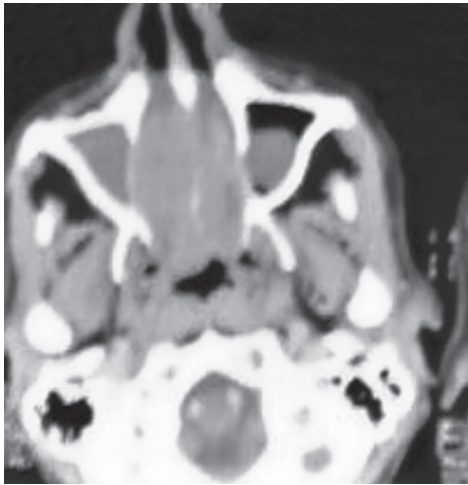


Fig 2: CT scan of a patient with adenoid cystic carcinoma. Tumor was seen filling the bilateral nasal cavity with erosion of septum. During surgery, the tumor was seen arising from posterior end of nasal septum and extending into bilateral nasal cavity

provided by the optics of the endoscope enhances better tumor visualization and improved disease clearance. Early postoperative recovery with very minimal complications and lesser hospital stay is another major advantage of endoscopic excision.^{22–24} Also, there is better cosmesis and better quality of life after endoscopic excision.²⁴

LIMITS OF ENDOSCOPIC EXCISION IN NASAL MALIGNANCY

The main limit of endoscopic surgery is the bleeding potential of highly vascular malignancies. Even a moderate amount of bleeding compromises endoscopic visualization, which in turn may make an endoscopic excision impossible. Tumor factors, such as involvement of anterior wall of the maxilla, significant intraorbital or intracranial extension with brain parenchymal involvement, extension into facial soft tissues, vascular invasion (ICA, cavernous sinus), optic chiasma invasion, anterior +/- lateral involvement of frontal sinus are some of the contraindications for endoscopic surgery (with curative intent) (Table 4).^{9,25}

SURGICAL OUTCOME AFTER ENDOSCOPIC RESECTION OF SINONASAL MALIGNANCIES

Various factors, such as T stage of tumor, intracranial extension, tumor histology, and mucosal margin status on histopathology decides the survival outcome.¹⁷ Studies have shown that one can achieve a 5-year overall, disease-specific, and recurrence-free survival rate of 92.9%, 100%, and 92.9%, respectively in esthesioneuroblastoma when operated endoscopically with adjuvant radiotherapy +/- chemotherapy.²⁶ Studies have also reported favorable surgical outcome with 5-year disease-specific survival of around 87–91%.^{27,28} in various sinonasal malignancies treated purely endoscopically. Such improved outcome in endoscopic group compared with open excision could be attributed to the fact that tumors operated via open approach were of aggressive tumors with fairly advanced stage.²⁹ Tumors operated via endoscopic approach show better survival outcome with lesser postoperative morbidity.

ROLE OF ADJUVANT THERAPY IN SINONASAL MALIGNANCY

In sinonasal malignancy, improved survival outcome is seen in patients treated with surgery followed by adjuvant radiotherapy than isolated radiotherapy.³⁰ Radiation-induced retinopathy and neuropathy were common adverse effects after conventional radiotherapy due to close proximity to optic nerves and eye ball.³¹ However, advancements in radiotherapy techniques like

Table 4: Advantages and limitations of endoscopic excision

Advantages	Limitations/Disadvantages
Shorter hospital stay	Highly vascular lesions are not suitable for endoscopic resection
Faster recovery	Relative contraindications for endoscopic excision: Involvement of anterior wall of maxilla, significant intraorbital or intracranial extension with brain parenchymal involvement, extension into facial soft tissues, vascular invasion (ICA, cavernous sinus), optic chiasma invasion, anterior +/- lateral involvement of frontal sinus
Lesser morbidity	Need for advanced skull base endoscope treatment unit with facilities like high speed drill system, endo-Doppler probe, neuro navigation, etc.
Improved cosmesis	Higher cost
Fewer complications	Need for highly skilled surgical expertise

3D conformational radiotherapy, IMRT (Intensity Modulated Radiotherapy), and IGRT (Image-guided Radiotherapy) have helped in reducing treatment-related complications drastically.³² For tumors showing orbital extension, orbit preservation can be achieved by using neoadjuvant chemotherapy or chemoradiotherapy in selected cases.^{33–36} For patients with locally advanced disease with doubtful operability, improved overall survival can be achieved with neoadjuvant therapy (radiotherapy/chemotherapy/chemoradiotherapy).⁵ These results emphasize the need for multimodality therapy for the management of sinonasal malignancy.

CONCLUSION

Careful case selection is essential for endoscopic excision of sinonasal malignancy. Surgery should only be performed by trained surgeons in a center with advanced facilities for endoscopic surgery. A high level of expertise in endoscopic sinus surgery and skull base and/or dural reconstruction is a necessity before undertaking endoscopic resections. Majority of the patients will require adjuvant radiotherapy. Diligent tumor surveillance with nasal endoscopy and interval magnetic resonance imaging scans is a necessity following the treatment of sinonasal malignancy.

REFERENCES

- Kawaguchi M, Kato H, Tomita H, et al. Imaging characteristics of malignant sinonasal tumours. *J Clin Med* 2017;6(12):116. DOI: 10.3390/jcm6120116.
- Haerle SK, Gullane PJ, Witterick IJ, et al. Sinonasal carcinomas: epidemiology, pathology, and management. *Neurosurg Clin N Am* 2013;24(1):39–49. DOI: 10.1016/j.nec.2012.08.004.
- Forbes WS, Fawcitt RA, Isherwood I, et al. Computed tomography in the diagnosis of diseases of the paranasal sinuses. *Clin Radiol* 1978;29:501–511. DOI: 10.1016/s0009-9260(78)80037-3.
- Resto VA, Chan AW, Deschler DG, et al. Extent of surgery in the management of locally advanced Sinonasal malignancies. *Head Neck* 2008;30:222–229. DOI: 10.1002/hed.20681.
- Robin TP, Jones BL, Gordon OM, et al. A Comprehensive comparative analysis of treatment modalities for sinonasal malignancies. *Cancer* 2017; 123(16): 3040–3049. DOI: 10.1002/cncr.30686.
- Stelow EB, Bishop JA. Update from the 4th Edition of the World Health Organization Classification of Head and Neck Tumours: Tumors of the Nasal Cavity, Paranasal Sinuses and Skull Base. *Head Neck Pathol* 2017;11(1):3–15. DOI: 10.1007/s12105-017-0791-4.
- Gallet P, Nguyen DT, Russel A, et al. Intestinal and non-intestinal nasal cavity adenocarcinoma: impact of wood dust exposure. *European Ann Otorhinolaryngol, Head Neck Dis* 2018;135(6):383–387. DOI: 10.1016/j.anorl.2018.08.012.
- Mahalingappa YB, Khalil HS. Sinonasal malignancy: presentation and outcomes. *J Laryngol Otol* 2014;128;7:654–657. DOI: 10.1017/S0022215114001066.
- Lund VJ, Clarke PM, Swift AC, et al. Nose and paranasal sinus tumours: United Kingdom National Multidisciplinary Guidelines. *J Laryngol Otol* 2016;130(S2):S111–S118. DOI: 10.1017/S0022215116000530.
- El-Gerby KM, El-Anwar MW. Differentiating benign from malignant sinonasal lesions: feasibility of diffusion weighted MRI. *Int Arch Otorhinolaryngol* 2017;21(4):358–365. DOI: 10.1055/s-0036-1597323.
- Sasaki M, Eida S, Sumi M, et al. Apparent diffusion coefficient mapping for sinonasal diseases: differentiation of benign and malignant lesions. *Am J Neuroradiol* 2011;32(6):1100–1106. DOI: 10.3174/ajnr.A2434.
- Roxbury CR, Ishii M, Richmon JD, et al. Endonasal endoscopic surgery in the management of sinonasal and anterior skull base malignancies. *Head Neck Pathol* 2016;10(1):13–22. DOI: 10.1007/s12105-016-0687-8.
- Segal N, Gluck O, Bavnik Y, et al. The usefulness of preoperative biopsy in unilateral nasal masses. *Allergy Rhinol* 2014;5(2):e53–e55. DOI: 10.2500/ar.2014.5.0082.
- Helsel JC, Bardales RH, Mukunyadzi P. Fine-needle aspiration biopsy cytology of malignant neoplasms of the sinonasal tract: a review of 22 primary and metastatic tumors. *Cancer Cytopathol* 2003;99;2: 105–112. DOI: 10.1002/cncr.10956.
- Stammler H, Anderhuber W, Walch C, et al. Possibilities and limitations of endoscopic management of nasal and paranasal sinus malignancies. *Acta Otorhinolaryngol Belg* 1999;53(3):199–205. PMID: 10635393.
- Carrau RL, Kassam AB, Snyderman CH, et al. Endoscopic transnasal anterior skull base resection for the treatment of Sinonasal malignancies. *Oper Tech Otolaryngol* 2006;17:102–110. DOI: 10.1016/j.otot.2006.03.010.
- Snyderman CH, Gardner PA. How much is enough? Endonasal surgery for olfactory neuroblastoma. *Skull Base* 2010;20(5):309–310. DOI: 10.1055/s-0030-1253583.
- Castellnuovo PG, Delù G, Sberze F, et al. Esthesioneuroblastoma: endonasal endoscopic treatment. *Skull Base* 2006;16(1):25–30. DOI: 10.1055/s-2005-922097.
- Fortes FSG, Sennes L U, Carrau RL, et al. Endoscopic anatomy of the pterygopalatine fossa and the transpterygoid approach: development of a surgical instruction model. *Laryngoscope* 2008;118(1):44–49. DOI: 10.1097/MLG.0b013e318155a492.
- Hadad G, Bassagasteguy L, Carrau RL, et al. A novel reconstructive technique after endoscopic expanded endonasal approaches: vascular pedicle nasoseptal flap. *Laryngoscope* 2006;116(10):1882–1886. DOI: 10.1097/01.mlg.0000234933.37779.e4.
- Chakravarthi S, Gonen L, Monroy-Sosa A, et al. Endoscopic endonasal reconstructive methods to the anterior skull base. *Semin Plast Surg* 2017; 31(4):203–213. DOI: 10.1055/s-0037-1607274.
- Suh JD, Ramakrishnan VR, Chi JJ, et al. Outcomes and complications of endoscopic approaches for malignancies of the paranasal sinuses and anterior skull base. *Ann Otol Rhinol Laryngol* 2013;122(1):54–59. DOI: 10.1177/000348941312200110.
- Pai PS, Moiyadi A, Nair D. Endoscopic v/s conventional approach to sino-nasal tumours - What's the debate? *Indian J Surg Oncol* 2010;1(2):194–199. DOI: 10.1007/s13193-010-0032-8.
- Cavel O, Abergel A, Margalit N, et al. Quality of life following endoscopic resection of skull base tumours. *J Neurol Surg B Skull Base* 2012;73(2):112–116. DOI: 10.1055/s-0032-1301392.
- Solares CA, Ong YK, Snyderman CH. Transnasal endoscopic skull base surgery: what are the limits? *Curr Opin Otolaryngol Head Neck Surg* 2010;18(1):1–7. DOI: 10.1097/MO0.0b013e318328350035.
- Gallia GL, Asemota AO, Blitz AM, et al. Endonasal endoscopic resection of olfactory neuroblastoma: an 11-year experience. *J Neurosurg* 2018;131(1):238–244. DOI: 10.3171/2018.2.JNS171424.
- Nicolai P, Battaglia P, Bignami M, et al. Endoscopic surgery for malignant tumours of the sinonasal tract and adjacent skull base: a 10-year experience. *Am J Rhinol* 2008;22(3):308–316. DOI: 10.2500/ajr.2008.22.3170.
- Hanna E, DeMonte F, Ibrahim S, et al. Endoscopic resection of Sinonasal cancers with and without craniotomy: oncologic results. *Arch Otolaryngol Head Neck Surg* 2009;135(12):1219–1224. DOI: 10.1001/archoto.2009.173.
- Eloy JA, Viviero RJ, Hoang K, et al. Comparison of transnasal endoscopic and open craniofacial resection for malignant tumours of the anterior skull base. *Laryngoscope*. 2009;119:834–840. DOI: 10.1002/lary.20186.
- Jansen EP, Keus RB, Hilgers FJ, et al. Does the combination of radiotherapy and debulking surgery favour survival in paranasal sinus carcinoma? *Int J Radiat Oncol Biol Phys*. 2000;48(1):27–35. DOI: 10.1016/s0360-3016(00)00594-0.
- Katz TS, Mendenhall WM, Morris CG, et al. Malignant tumors of the nasal cavity and paranasal sinuses. *Head Neck* 2002;24(9):821–829. DOI: 10.1002/hed.10143.

32. Claus F, De Gerssem W, De Wagter C, et al. An implementation strategy for IMRT of ethmoid sinus cancer with bilateral sparing of the optic pathways. *Int J Radiat Oncol Biol Phys* 2001;51(2):318–331. DOI: 10.1016/s0360-3016(01)01627-3.
33. Amsbaugh MJ, Yusuf M, Silverman C. Organ preservation with neoadjuvant chemoradiation in patients with orbit invasive sinonasal cancer otherwise requiring exenteration. *Radiation Oncology Journal* 2016;34(3):209–215. DOI: 10.3857/roj.2016.01739.
34. Ojiri H, Ujita M, Tada S, et al. Potentially distinctive features of sinonasal inverted papilloma on MR imaging. *AJR Am J Roentgenol* 2000;175(2):465–468. DOI: 10.2214/ajr.175.2.1750465.
35. Som PM, Lidov M, Brandwein M, et al. Sinonasal esthesioneuroblastoma with intracranial extension: marginal tumor cysts as a diagnostic MR finding. *AJNR Am J Neuroradiol*. 1994;15(7):1259–1262. PMID: 7976934.
36. American Joint Committee on Cancer. Nasal cavity and paranasal sinuses. In: *AJCC Cancer Staging Manual*. 7th edition. New York, NY: Springer; 2010, pp. 69–73.