

# Risk of Thyroid Malignancy in Multinodular Goiter: A Prospective Study

Shruthi<sup>1</sup>, Praveen Kumar R Bhat<sup>2</sup>

## ABSTRACT

**Aim:** Aim of this study was to estimate the prevalence of thyroid malignancy in multinodular goiter cases and to describe the age, sex distribution, and pattern of thyroid malignancy in multinodular goiter.

**Materials and methods:** A prospective cross-sectional study was carried out on multinodular goiter cases received for histopathologic examination in department of pathology from July 2015 to June 2017. A total of 100 cases were included in the study. Descriptive analysis was performed using frequencies and percentages.

**Results:** Out of hundred patients operated for multinodular goiter, twelve patients had thyroid malignancy. Among 12 malignant cases, nine cases were papillary carcinoma and three were follicular carcinoma. Overall mean age of patients was 40 years. Mean age of patients with coexistent thyroid carcinoma was 39 years. Mean duration of goiter in those who had malignancy was 7.8 years, and that in those who had only goiter was 5.6 years. Overall male/female ratio was 6.14, and thyroid malignancy was seen in only females. Among papillary carcinoma, most common variant was microcarcinoma (four cases) followed by follicular variant (three cases) and conventional type (two cases).

**Conclusion:** There is increased risk of thyroid carcinoma in multinodular goiter. Hence, total thyroidectomy is a better option to treat patients with multinodular goiter. Papillary carcinoma is more common than follicular carcinoma in multinodular goiter.

**Clinical significance:** Total thyroidectomy is a better option to treat patients with multinodular goiter and, if treated conservatively, should be closely followed up.

**Keywords:** Follicular carcinoma thyroid, Histopathology, Multinodular goiter, Papillary carcinoma, Thyroid malignancy.

*Otorhinolaryngology Clinics: An International Journal* (2021): 10.5005/jp-journals-10003-1413

## INTRODUCTION

Thyroid gland is one of the most common endocrine glands to be affected by various disease processes.<sup>1</sup> Multinodular goiter (MNG) is the most common thyroid disorder, and 4–17% of these are found to harbor a carcinoma if carefully examined. The use of ultrasound-guided fine needle aspiration (FNA) for evaluating these patients is not clearly defined, and aspiration of all the numerous nodules is impractical.<sup>2</sup> Multinodularity of the goiter should not be considered as low risk of malignancy and delay for surgical intervention. Changes in the size of gland, the appearance of new and hard nodules, or cervical lymphadenopathy may indicate malignant change and prompt indication for surgery.<sup>1</sup> Total thyroidectomy has emerged as a surgical option to treat patients with multinodular goiter, in order to prevent dissemination of malignant disease, especially in endemic iodine-deficient regions.<sup>3</sup>

Aim of this study was to estimate the prevalence of thyroid carcinoma in multinodular goiter cases and to describe the age, sex distribution, and pattern of thyroid malignancy in multinodular goiter.

## MATERIALS AND METHODS

A prospective cross-sectional study was carried out on multinodular goiter cases received for histopathologic examination in department of pathology from July 2015 to June 2017. A total of 100 cases were included in the study. Details of all cases consisting of clinical history, gross features, microscopic features, and final diagnosis were analyzed. Descriptive analysis was performed using frequencies and percentages. Institutional Ethics Committee approval was taken.

<sup>1</sup>Department of Pathology, KS Hegde Medical Academy, Nitte (Deemed to be University), Mangaluru, Karnataka, India

<sup>2</sup>Department of General Surgery, KS Hegde Medical Academy, Nitte (Deemed to be University), Mangaluru, Karnataka, India

**Corresponding Author:** Praveen Kumar R Bhat, Department of General Surgery, KS Hegde Medical Academy, Nitte (Deemed to be University), Mangaluru, Karnataka, India, Phone: +91 7718006949, e-mail: drpraveenbhatmmc@gmail.com

**How to cite this article:** Shruthi, Bhat PKR. Risk of Thyroid Malignancy in Multinodular Goiter: A Prospective Study. *Int J Otorhinolaryngol Clin* 2021;x(x):xx–xx.

**Source of support:** Nil

**Conflict of interest:** None

## RESULTS

Out of hundred patients operated for multinodular goiter, twelve patients had thyroid malignancy (Fig. 1).

Among 12 malignant cases, nine cases were papillary carcinoma and three were follicular carcinoma (Fig. 2).

## DISCUSSION

Multinodular goiter is the most common thyroid disorder, and 4–17% of these can undergo malignant change.<sup>2</sup> Present study consisted of 100 patients operated for multinodular goiter. Overall mean age of patients was 40 years. Mean age of patients with coexistent thyroid carcinoma was 39 years which is lesser compare to other studies. Age range was 22–56 years

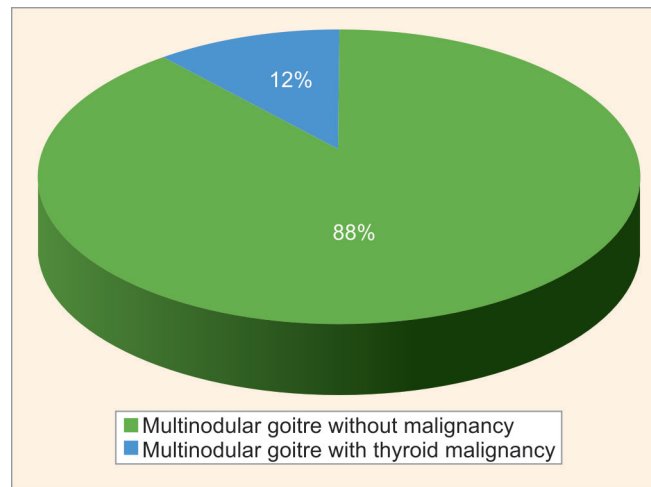


Fig. 1: Frequency of malignancy in multinodular goiter

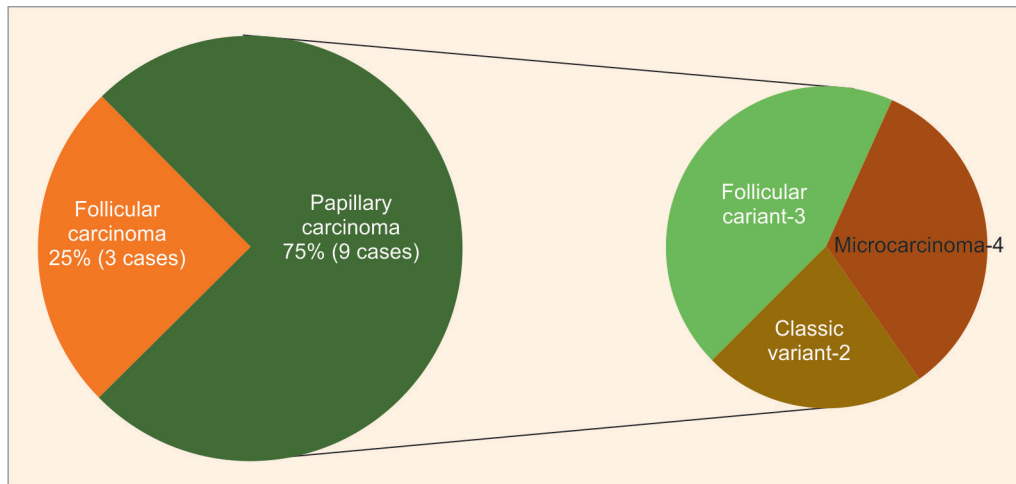


Fig. 2: Spectrum of thyroid malignancy in multinodular goiter

Table 1: Age and sex distribution of multinodular goiter

Age-group (in years)		Multinodular goiter without malignancy	Multinodular goiter with malignancy
1–10	Males	0	0
	Females	1	0
11–20	Males	0	0
	Females	4	0
21–30	Males	2	0
	Females	16	5
31–40	Males	5	0
	Females	21	1
41–50	Males	4	0
	Females	17	2
51–60	Males	1	0
	Females	7	4
61–70	Males	2	0
	Females	6	0
71–80	Males	1	0
	Females	0	0

(Table 1). Koh et al.<sup>4</sup> reported mean age of 35 years for benign goiters and 46 years for goiters with carcinoma. Similarly, another study reported carcinoma in above 45 years age-group.<sup>5</sup> Mean duration of goiter in those who had malignancy was longer (7.8 years), and that in those who had only goiter was 5.6 years, which indicates the increased risk of thyroid malignancy in longstanding nodular goiter. In a study by Rahman et al.,<sup>1</sup> mean duration of presenting symptoms in those who had malignancy in multinodular goiter was 10.2 years and that in those patients who had only multinodular goiter was 5.91 years. Overall male/female ratio was 6.14, and thyroid malignancy was seen in only females. Similarly, female preponderance was reported by various studies.<sup>5,6</sup>

Out of hundred patients, twelve patients (12%) had thyroid malignancy, among which nine cases were papillary carcinoma and three were follicular carcinoma. Various studies have reported malignancy in 7–21% of cases operated for multinodular goiter (Table 2). In multinodular goiter, papillary carcinoma is more common than follicular carcinoma which is contrary to various text books.<sup>7,8</sup> However, studies have reported papillary carcinoma more common than follicular carcinoma (Table 3). Among papillary carcinoma, most common variant was microcarcinoma

**Table 2:** Prevalence of carcinoma in multinodular goiter in various studies

Various studies (n = sample size)	Thyroid malignancy
Rahman et al. <sup>1</sup> (n = 50)	10%
Koh et al. <sup>4</sup> (n = 107)	7.5%
Gandolfi et al. <sup>5</sup> (n = 58)	13.7%
Nanjappa et al. <sup>6</sup> (n = 175)	21%
Yong et al. <sup>9</sup> (n = 223)	14.3%
Present study (n = 100)	12%

**Table 3:** Histologic type of carcinoma in multinodular goiter in various studies

Various studies	Papillary carcinoma (%)	Follicular carcinoma (%)	Medullary carcinoma (%)	Others (%)
Rahman et al. <sup>1</sup>	80	20	—	—
Koh et al. <sup>4</sup>	50	25	12.5	12.5
Gandolfi et al. <sup>5</sup>	63	37	—	—
Yong et al. <sup>9</sup>	94.4	5.6	—	—
Present study	75	25	—	—

(four cases) followed by follicular variant (three cases) and conventional (two cases) type (Fig. 2). However, another study has reported follicular variant as common type than microcarcinoma.<sup>9</sup>

## CONCLUSION

There is increased risk of thyroid carcinoma in multinodular goiter. Hence, total thyroidectomy has emerged as a better option to treat patients with multinodular goiter, especially in iodine-deficient regions. If total thyroidectomy is not performed, abnormal thyroid tissue left behind may have malignant potential. All patients with a multinodular goiter treated conservatively should be closely

followed up. Papillary carcinoma is more common than follicular carcinoma in multinodular goiter.

## Clinical Significance

Total thyroidectomy is a better option to treat patients with multinodular goiter and, if treated conservatively, should be closely followed up.

## ORCID

Shruthi  <https://orcid.org/0000-0001-7676-8372>

Praveen Kumar R Bhat  <https://orcid.org/0000-0002-7972-2625>

## REFERENCES

1. Rahman MM, Ali MI, Karim MA, et al. Frequency of malignancy in multinodular goitre. *Bangladesh J Otorhinolaryngol* 2014;20(2):75–79. DOI: 10.3329/bjo.v20i2.22022.
2. Neto GM. Multinodular goiter. In: Feingold KR, Anawalt B, Boyce A, et al., editors. *Endotext* [Internet]. South Dartmouth (MA): MDText.com, Inc.; 2000. Available from: <https://www.ncbi.nlm.nih.gov/books/NBK285569/?report=classic>.
3. Yasemine G, Harika B, Terzioglu T, et al. The advantage of total thyroidectomy to avoid reoperation for incidental thyroid cancer in multinodular goiter. *Arch Surg* 2004;139(2):179–182. DOI: 10.1001/archsurg.139.2.179.
4. Koh KBH, Chang KW. Carcinoma in multinodular goitre. *Br J Surg* 1992;79(3):266–267. DOI: 10.1002/bjs.1800790328.
5. Gandolfi PP, Frisina A, Raffa M, et al. The incidence of thyroid carcinoma in multinodular goiter: retrospective analysis. *Acta Med* 2004;75(2):114–117. PMID: 15481700.
6. Nanjappa BAN, Mohanty A, Aroul TT, et al. Thyroid carcinoma (Tc) in nodular goitre. *Thyroid Disord Ther* 2012;1(3):1–3. DOI: 10.4172/2167-7948.1000115.
7. Maitra A. Thyroid glands. In: Vinay Kumar, Abbas AK, Aster JC, editors. *Robbins and cotrans pathologic basis of disease*. 10th ed. Philadelphia: Saunders; 2015. p. 1075–1092.
8. Nixon IJ, Adamson RM. The thyroid gland. In: Williams NS, O'Connell PR, McCaskie AW, editors. *Bailey & Love's short practice of surgery*. 27th ed. Boca Raton, FL: CRC Press; 2018. p. 800–822.
9. Yong JS, Loh KS, Petersson BF, et al. Multinodular goiter: a study of malignancy risk in nondominant nodules. *Ear Nose Throat J* 2017;96(8):336–342. DOI: 10.1177/014556131709600821.