ORIGINAL RESEARCH ARTICLE

The Peroneal Vessels as Recipient in Free Flaps for Defects near the Ankle: An Alternative to the Anterior Tibial Vessels

Parvathi Ravula[1], Prakash Panagatla[2], Lalith Mohan Chodavarapu[3], Srikanth Rangachari[4], Kinnera SV[5]

Received on: 20 June 2022; *Accepted on:* 16 August 2022; *Published on:* xxxx

Abstract

Background: Extensive anterolateral defects involving the lower leg, ankle, and proximal foot usually need the use of free flaps for optimal coverage. Usually, anterior tibial vessels are used as recipient vessels for such defects, but in situations where these vessels are not usable either because of a large zone of trauma or pre-existing scarring that may preclude the use of anterior tibial vessels without the use of a vein graft, peroneal vessels can be considered as the recipient vessel.

Materials and methods: This retrospective series of six cases define the indications and the outcomes of peroneal vessels as a recipient.

Results: In two of six cases, a preliminary exploration of the anterior tibial vessels revealed a non-usable situation. In the other four cases with similar clinical conditions, deliberate exploration of peroneal vessels after excising a segment of the fibula ensured the availability of a healthy recipient for a successful outcome.

Discussion: In four cases, there was no morbidity on account of the fibular excision. Two developed ankle instability, but the nature of the injury was partially an attributable cause.

Conclusion: The peroneal vessels need to be considered in preference to the posterior tibial as a recipient in extensive anterolateral lower third leg and foot defects crossing the ankle when the anterior tibial is in the zone of trauma or surrounded by scarring.

Keywords: Ankle contracture, Lower limb defects, Peroneal vessels, Recipient vessels.

Journal of Foot and Ankle Surgery (Asia-Pacific) (2022): 10.5005/jp-journals-10040-1270

Introduction

Chen et al.[1] reported one of the earliest series of 126 cases of compound tibial fractures needing free flap coverage, analyzing the choice of recipient vessels. They stated a great chance of injury to the anterior tibial vessels; further, that an injury of the posterior tibial vessels was usually accompanied by an injury of the anterior tibial—implying the need to use the posterior tibial for revascularization and the anterior tibial as free flap recipient vessels. They comment that the peroneal artery being deeply situated was cumbersome as a choice for the recipient vessel.

The peroneal artery has a course deep to the interosseous membrane through the substance of the flexor hallucis longus in the middle and lower third of the leg. The anatomical consistency has made the free fibula flap and now the peroneal skin flap a reliable flap. This is familiar territory to most microsurgeons, and hence the peroneal artery can be considered a recipient vessel source in certain situations.

In fact, the use of a free flap based on perforators of the lateral leg, wherein the peroneal vessels were harvested to increase pedicle length, was reported in 1984 by Yoshimura et al. and Nakashima et al.[2,3]

Chaivanichsiri,[4] in a cohort of 107 cases needing free flaps for the leg of varying indications, reported a reduction in flap failure rates from 25 to 7% just on the strength of correctly choosing the recipient vessels away from the zone of trauma.

Not having alternative sources for the recipient pedicle may force the usage of suboptimal vessels in the zone of trauma, putting the flap at risk or resulting in an abort of the free flap procedure. An end-to-side anastomosis to the uninjured anterior or posterior tibial is a possibility if the peroneal vessels are not considered, but this choice has to be tempered by the location and size of the defect. In the absence of a healthy anterior tibial pedicle close to the defect, the peroneal vessels are the alternate choice for defects located in the anterolateral leg and ankle.

This study is a retrospective series to define the indications of choosing the peroneal vessels as the recipient in free flap transfer for anterolateral defects of the ankle and lower leg.

[1,2,4,5]Department of Plastic and Reconstructive Surgery, Nizam's Institute of Medical Sciences, Hyderabad, Telangana, India

[3]Department of Orthopedics, Nizam's Institute of Medical Sciences, Hyderabad, Telangana, India

Corresponding Author: Kinnera SV, Department of Plastic and Reconstructive Surgery, Nizam's Institute of Medical Sciences, Hyderabad, Telangana, India, Phone: +91 9686696590, e-mail: kinneraseelapu@gmail.com

How to cite this article: Ravula P, Panagatla P, Chodavarapu LM, *et al.* The Peroneal Vessels as Recipient in Free Flaps for Defects near the Ankle: An Alternative to the Anterior Tibial Vessels. J Foot Ankle Surg (Asia-Pacific) 2022;xx(xx):1–5.

Source of support: Nil

Conflict of interest: None

Materials and Methods

A retrospective analysis of all lower limb free flaps over a 5-year period (2014–2019) was done to retrieve data on cases in which the peroneal vessels were used as the recipient. Defects of the lower third, ankle and proximal dorsum of the foot were used as the criteria for understanding the rationale of use of the peroneal vessels. Fractured bones of the lower third leg were excluded, as the harvest of the peroneal vessels could be associated with

morbidity. There were 127 such cases where the defect was as described above. The anterior tibial was the recipient vessel in 91 cases, and the posterior tibial was in 36 cases. A total of 110 flaps survived completely, and there were 16 flap losses.

During the same period, there were six cases in which the peroneal vessels were used—three were males, and three were females; the age range was 6–45 years. Three were elective, and three were for emergency indications. The nature of the defect was acute trauma in two, burn deformity of the ankle in two (Figs 1A to J), and ankle contracture as a sequela of necrotizing infection in two (Figs 2A to F). None of the patients had any comorbidities. Neither of the acute trauma cases had an injury to the leg bones proximal to the ankle joint. All the defects involved the anterolateral aspect of the lower third of the leg or the corresponding area on the ankle joint or dorsum of the foot (Figs 3A to G) (Table 1).

In two of the six cases, the peroneal vessels had been used after a preliminary exploration of the anterior tibial vessels revealed unsuitability.

In the other four, direct exploration of the peroneal pedicle was done, anticipating the nonavailability of healthy anterior tibial vessels or the location of a healthy recipient would imply difficulty in adequate coverage of the distal defect. Exploration of the peroneal vessels was done using a skin incision at the anterior border of the lower third of the fibula (except in the two cases where the incision to expose the anterior tibial pedicle was extended laterally). In all the cases, access to the peroneal vessels implied the removal of a 5–7 cm length of the fibula in the middle third of the leg.

Pulsatile flow after tourniquet deflation determined the suitability of the recipient vessels. In addition, it was confirmed that the posterior tibial artery was perfusing the foot. At the end of the anastomosis procedure, the fibular segment was discarded to prevent inadvertent injury at the anastomotic site if it were to be placed back.

Results

The mean defect size in the six cases was 163 cm^2.

In five of the cases, an anterolateral thigh flap was used, and the latissimus dorsi muscle with split skin graft in one case. The donor site of the anterolateral thigh flap was closed primarily in one of the five cases.

There was one reexploration on account of venous congestion postoperatively, and found to be due to a hematoma at the site of the anastomosis; no revision of the anastomosis was needed. In addition, one of the six patients needed a secondary split skin graft due to the loss of a skin graft over the latissimus dorsi muscle.

The follow-up period ranged from 3 months to 6 years.

Figs 1A to J: (A to C) Preoperative pictures showing postburn dorsal contracture of the ankle; (D) Excision of fibula segment (arrow) to access the peroneal vessels; (E) Anterolateral thigh flap; (F) Flap inset over the defect; (G to J) A 5-year follow-up showing plantigrade foot permitting weight-bearing

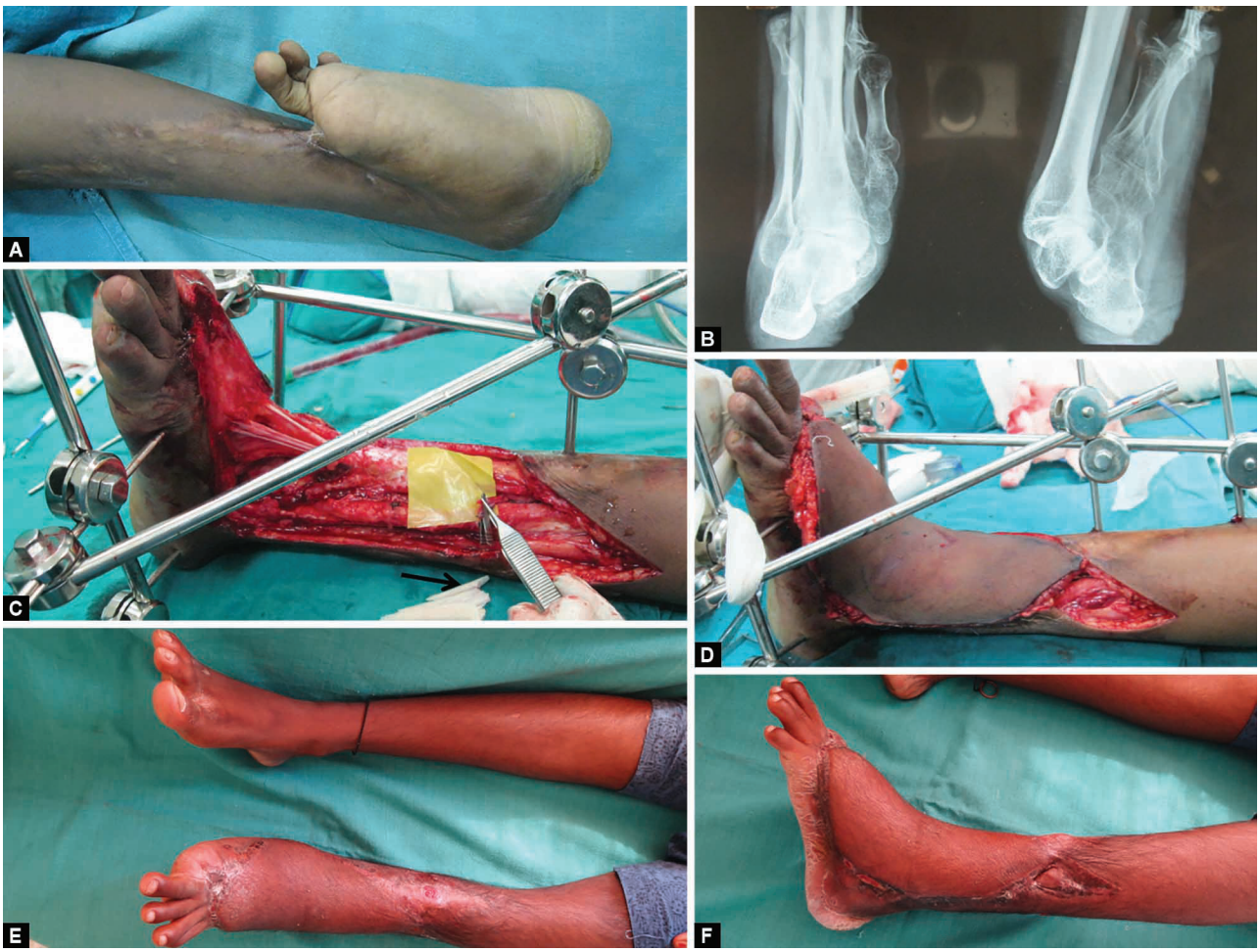

Figs 2A to F: (A and B) Postinfective ankle contracture with X-ray showing dorsiflexion deformity; (C) Contracture release permitting plantigrade foot and exposure of the peroneal vessels, arrow indicates removed fibula; (D) Completion of flap inset; (E and F) A 33-month follow-up with no recurrence of deformity

Four of the six cases had no morbidity on account of the removal of a segment of the fibula for accessing the peroneal pedicle.

One case needing a free flap for the weight-bearing heel (acute trauma) with partial instability of the heel developed further ankle instability necessitating formal ankle arthrodesis 9 months after the primary procedure; the said patient had also undergone below knee amputation of the contralateral lower limb for an unsalvageable injury.

The other case was a bilateral leg injury in a child (acute trauma) where the decision to do the free flap was to avoid a below-knee amputation; this patient also had an injury of the ankle mortise at presentation but presented for follow-up after 6 years with a deformed ankle but weight-bearing successfully (Figs 4A to F).

Discussion

Sailon et al.[5] reported a unique case where the peroneal artery, along with the flexor hallucis longus, was used as a carrier for a free rectus muscle flap in knee wound coverage; further, they did cadaver studies to delineate the anatomy of the origin of the peroneal artery in relation to the fibular head.

Haddock et al.[6] reported 191 microvascular reconstructions for lower limb injuries—127 (57.2%) used the posterior tibial, 59 (26.6%) used the anterior tibial and the peroneal only in eight (3.6%) cases; in 28 (12.6%) other vessels (including sural artery, popliteal artery, and genicular arteries) were used.

Hence the indications for the use of the peroneal vessels are uncommon, but this has to be taken into the context of defect location. The nearest uninjured vessel for defects in the region of the ankle and proximal foot are the three axial leg vessels. If vein grafts are to be avoided, then the peroneal is the logical alternative to the anterior tibial vessel.

Elswick et al.[7] reported using the peroneal vessels as the recipient after exploration revealed inadequate hypoplastic posterior tibial vessels; the author stressed a medial approach for isolating the peroneal artery; a parascapular free flap used to cover skin loss at the anterior ankle using the peroneal vessels through a medial approach.

In the present series, where a preliminary exploration of the anterior tibial could not deliver healthy recipient vessels, the same incision was extended to deliver the peroneal and was logical to ensure a straight course from the site of the recipient vessel to the defect.

Lee et al.[8] reported the use of the Anterolateral thigh flaps in seven forefoot burn contractures (mean duration of 26.8 years) with 100% success using the anterior tibial vessels only; the contractures in their series were limited to the distal foot. In the present study of the three cases with contractures, two were postinfective, and the third had contractures more proximally in the ankle. In such a situation, healthy anterior tibial vessels, if at all available, would be

Figs 3A to G: (A and B) Valgus deformity of the right ankle following split skin grafting of crush injury leg and foot; (C and D) X-ray of the foot; (E) Exposure of peroneal vessels after excision of the fibular segment (arrow) and excision of the ankle scar; (F) Flap inset (G) A 19-month follow-up images

Table 1: Details of the defects, reconstruction, and outcomes

No.	*Cause*	*Condition*	*First pedicle dissected*	*Defect size (cm)*	*Fibular excision complications*	*Follow-up period*
1	Electric burns	Exposed ankle joint and tarsals	Anterior tibial	12 × 10	None	3 months
2	Posttraumatic (Figs 3A to G)	Valgus deformity ankle, planned for future ankle arthrodesis	Peroneal	17 × 10	None	19 months
3	Postinfective (Figs 2A to F)	Ankle contracture	Anterior tibial	20 × 12	None	33 months
4	Acute trauma (Figs 4A to F)	Avulsion of leg and ankle	Peroneal	15 × 10	Deformed ankle*	6 years
5	Acute trauma	Heel avulsion with ankle fracture	Peroneal	12 × 10	Ankle instability	12 months
6	Burns (Figs 1A to J)	Burn contracture ankle and foot	Peroneal	15 × 12	None	5 years

*The deformity was in part due to the long period of absence from follow-up care

far away from the defect to permit wound coverage without the use of interposition vein grafts. The peroneal pedicle behind the interosseous membrane would be available at a closer distance to allow complete wound coverage.

Kang et al.[9] reported a small series of 52 free flaps for mixed free flap indications in the leg and the foot, showing the use of the peroneal artery as a recipient in <0.5% of cases.

Yazar and Lin[10] published a series of 574 free flaps where only eight cases had the use of the peroneal artery (1%) as the recipient vessel. There is no indication in the study of the subset of defects needing the use of the peroneal artery as against the other vessels. They do mention the lesser chance of injury to the peroneal vessels in the situation where both the anterior tibial and posterior tibial vessels are injured.

Singh et al.[11] reported nine cases using the peroneal vessels in a cohort of 182 free flaps in the lower limb—three in diabetics and six in trauma. The advantage of using the peroneal that the authors cite is the possibility of avoiding the use of vein grafts to the other two conventionally used anterior or posterior tibial vessels beyond the zone of trauma. In diabetics, the authors proceed with caution and elect to do an end-to-side anastomosis, preserving runoff to the foot. All the defects were around the lateral ankle, and delivery of the vessels was facilitated by the excision of a 5 cm segment of the fibula. They do not report any complications consequent to the mandatory excision of the fibular segment.

In our series, only two patients with acute trauma had ankle instability (treated subsequently in one)—partly on account of

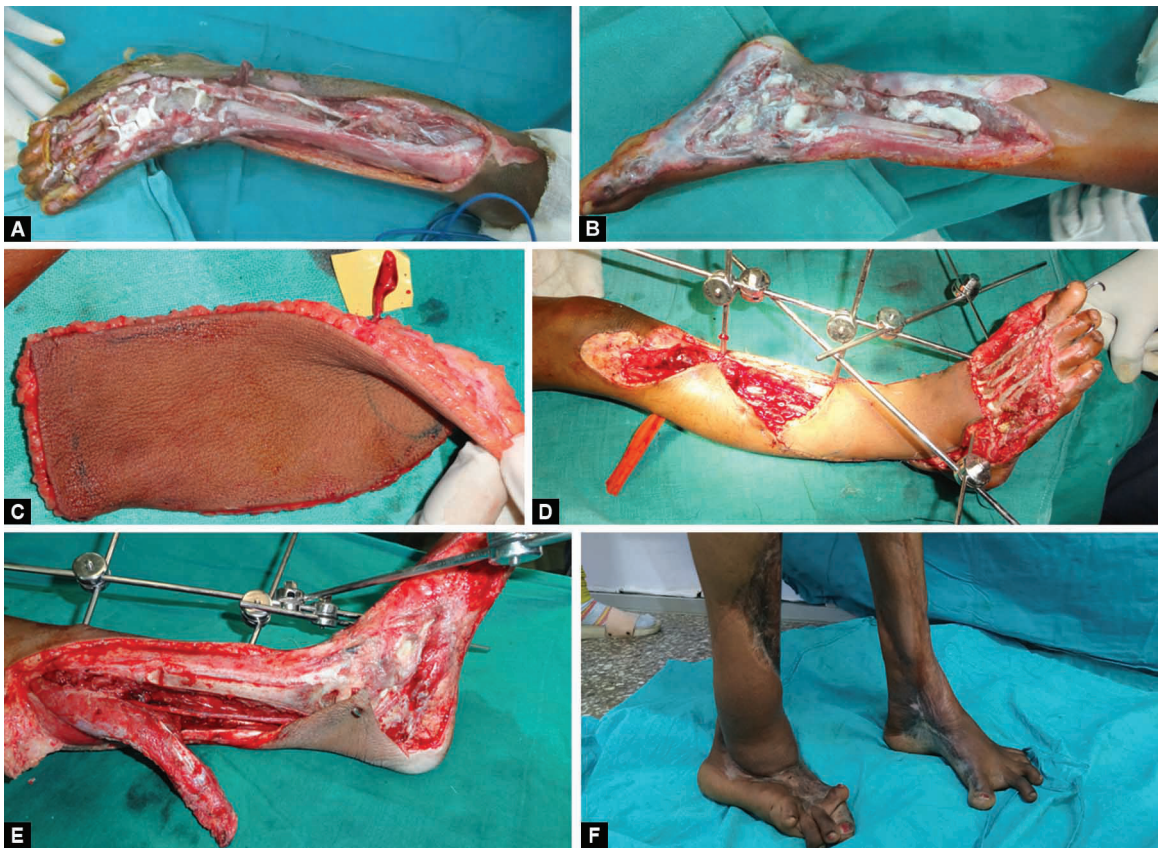

Figs 4A to F: (A and B) Preoperative images of bilateral crush injury leg and ankle; (C) Anterolateral thigh flap harvested from the left thigh; (D) Flap used for coverage of the right ankle and proximal foot after anastomosis to the peroneal vessels; (E) Proximal-based soleus flap for coverage of critical defect on left leg; (F) A 6-year follow-up images showing valgus deformity of the right ankle; mild inversion deformity with forefoot adduction on the left foot

injury causing ankle instability even before the excision of the fibular segment. One had an amputated opposite lower limb, and the other child had a bilateral lower limb injury needing aggressive attempts at limb salvage.

Conclusion

A deeper location of the peroneal does not preclude its use as a recipient vessel for the free flap, especially in the presence of a significant injury to the anterior tibial vessels. In fact, its position behind the fibula could make it a privileged site and not be subject to fibrosis and scarrings like the anterior tibial in severe contractures or extensive trauma.

The indications are the presence of a defect located in the anterolateral leg or ankle. This approach would permit the avoidance of interposition vein grafts if the anterior tibial vessels were to be used.

Removal of a fibular segment facilitates the pedicle retrieval provided such is reserved for situations without ankle joint instability to prevent the possibility of future ankle deformity.

The authors do agree that the method has a restricted application on account of the mandatory removal of the fibular segment but is of valuable use when there are few safe alternatives to free flaps for defects in the said location.

References

1. Chen HC, Chuang CC, Chen S, et al. Selection of recipient vessels for free flaps to the distal leg and foot following trauma. Microsurgery 1994;15(5):358–363. DOI: 10.1002/micr.1920150514
2. Yoshimura M, Imura S, Shimamura K, et al. Peroneal flap for reconstruction in the extremity: preliminary report. Plast Reconstr Surg 1984;74(3):402–409. DOI: 10.1097/00006534-198409000-00013
3. Nakashima H, Araki Y, Nishikido E, et al. Free peroneal flap for wide skin defects of the foot and volar scar contracture of the hand. J Reconstr Microsurg 1987;3(2):105–111. DOI: 10.1055/s-2007-1006972
4. Chaivanichsiri P. Influence of recipient vessels on free tissue transplantation of the extremities. Plast Reconstr Surg 1999;104(4):970–975. DOI: 10.1097/00006534-199909040-00011
5. Sailon AM, Reformat DD, Hecht EM, et al. The proximally based peroneal vascular bundle: an insulated extension cord for free flap reconstruction. Ann Plast Surg 2009;62(5):556–559. DOI: 10.1097/SAP.0b013e31819fb092
6. Haddock NT, Weichman KE, Reformat DD, et al. Lower extremity arterial injury patterns and reconstructive outcomes in patients with severe lower extremity trauma: a 26-year review. J Am Coll Surg 2010;210(1):66–72. DOI: 10.1016/j.jamcollsurg.2009.09.040
7. Elswick SM, Miglani A, Lettieri SC. Medial approach to the peroneal vessels as recipients for free flap reconstruction of the leg. Microsurgery 2020;40(2):229–233. DOI: 10.1002/micr.30462
8. Lee SH, An SJ, Kim NR, et al. Reconstruction of postburn contracture of the forefoot using the anterolateral thigh flap. Clin Orthop Surg 2016;8(4):444–451. DOI: 10.4055/cios.2016.8.4.444
9. Kang MJ, Chung CH, Chang YJ, et al. Reconstruction of the lower extremity using free flaps. Arch Plast Surg 2013;40(5):575–583. DOI: 10.5999/aps.2013.40.5.575
10. Yazar S, Lin CH. Selection of recipient vessel in traumatic lower extremity. J Reconstr Microsurg 2012;28(3):199–204. DOI: 10.1055/s-0032-1306366
11. Singh H, Jain A, Mahendru S. Peroneal pedicle: an underutilized recipient vessel. Turk J Plast Surg 2020;28(3):146–151. DOI: 10.4103/tjps.tjps_55_19