

# Clinical Outcomes in Partial Cricotracheal Resection and Anastomosis in Subglottic and Upper Tracheal Stenosis: A 10-year Institutional Study

Izhak Mehadi<sup>1</sup>, Sanjeev Mohanty<sup>2</sup>, Vinoth Manimaran<sup>3</sup>

## ABSTRACT

**Objective:** The study aimed to review the clinical and surgical outcomes of partial cricotracheal resection (PCTR) and anastomosis in the management of laryngotracheal stenosis (LTS).

**Materials and methods:** The study used a retrospective analysis of adult patients managed in a University Hospital who underwent PCTR and anastomosis from 2007 to 2017.

**Results:** During the 10 years, 53 patients were diagnosed with cricotracheal or tracheal stenosis. Prolonged orotracheal intubation and blunt trauma were the leading causes of upper LTS. The stenosis were classified as per Myer-Cotton classification. Thirty-seven were chosen for surgical intervention. Of the patients who underwent surgical intervention, PCTR was done in 33, resection and anastomosis in 3 and 1 underwent balloon dilatation. Tube displacement and surgical emphysema were the most common complication seen postoperatively. Ninety-seven percent of the patients who underwent surgery were successfully decannulated.

**Conclusion:** Partial cricotracheal resection is an established surgical procedure with low morbidity and mortality. Risk factors for increased morbidity include diabetes melitus (DM), lengthy resection, and children. Rib autograft was found to be ideal for reconstruction. Prompt observation and intervention of morbidity is the key to good clinical outcomes.

**Keywords:** Partial cricotracheal resection and anastomosis, Subglottic stenosis, Tracheal stenosis.

*International Journal of Head and Neck Surgery* (2020); 10.5005/jp-journals-10001-1416

## INTRODUCTION

Partial or complete narrowing of the subglottic area may be congenital or acquired. Throughout the last decade, laryngotracheal stenosis (LTS) has become a prominent pathological condition among otolaryngologists. The problems the patient brings to the physician are rare and challenging. The condition affects both the soft tissue and cartilage support. The increased use of orotracheal intubation and tracheotomy may explain the increased incidence of this condition.

The management strategy included endoscopic dilatation, stent placement, and tracheostomy. Surgical resection with end-to-end anastomosis was described and taken into practice during the early 1970s. Through surgical evolution and breakthrough in modern medicine, partial cricotracheal resection (PCTR) has become the standard mode of management in patients with symptomatic LTS in many centers. The intervention has a postoperative decannulation rate approaching 90%.<sup>1</sup>

## MATERIALS AND METHODS

A retrospective study was done for patients admitted with a diagnosis of tracheal and subglottic stenosis to the Department of Otorhinolaryngology, Sri Ramachandra Medical College and Research Institute, Chennai. Fifty-three candidates were diagnosed with LTS. The stenotic segment was evaluated *via* endoscopy and classified as per Myer-Cotton classification.<sup>2</sup> The stenotic segment was also evaluated by computed tomographic imaging. The majority of the candidates who presented fell into grade I (64%). Thirty-seven patients were selected for surgical intervention. Of these, 33 underwent PCTR, 3 underwent resection and anastomosis

<sup>1,3</sup>Department of Otorhinolaryngology, Sri Ramachandra Medical College and Research Institute, Chennai, Tamil Nadu, India

<sup>2</sup>Department of ENT, Head and Neck Surgery, Sri Ramachandra Medical College and Research Institute, Chennai, Tamil Nadu, India

**Corresponding Author:** Izhak Mehadi, Department of Otorhinolaryngology, Sri Ramachandra Medical College and Research Institute, Chennai, Tamil Nadu, India, Phone: +91 8939472590, e-mail: dr.izhakmehadi@gmail.com

**How to cite this article:** Mehadi I, Mohanty S, Manimaran V. Clinical Outcomes in Partial Cricotracheal Resection and Anastomosis in Subglottic and Upper Tracheal Stenosis: A 10-year Institutional Study. *Int J Head Neck Surg* 2020;XX(X):1–3.

**Source of support:** Nil

**Conflict of interest:** None

of the tracheal stenotic segment and one patient underwent balloon dilatation. Our study put a focus on the candidates who underwent PCTR. Only candidates that fell in the Myer-Cotton grade II and above were considered for surgical intervention. The remaining 16 patients were managed conservatively.

## Surgical Technique

All patients planned for surgical intervention were tracheostomized before PCTR. A cervical collar incision was performed and skin flaps were elevated for exploration. Strap muscles were dissected from the midline to visualize the larynx and trachea. The vertical incision was performed on the side of the stenotic segment and the laryngotracheal lumen was entered. Airway examination was performed for a re-evaluation of the stenotic segment

and cricoid cartilage. The non-stenotic superior portion of the anterior arch of the cricoid cartilage is preserved. The subglottic stenotic segment along with a portion of the upper trachea in continuity is the subglottis is resected. The resected portion is fixed and anastomosed with the harvested rib autograft. The inner perichondrial surface faced the lumen. The freshly placed autograft was sutured using 4-0 absorbable sutures, such that the thicker section was placed superiorly and the thinner section inferiorly (Fig. 1).

Montgomery T-tube was subsequently placed for stenting. Postoperatively, the patient continued intubation for a period of 24 hours with antibiotic cover for 5 days. Endoscopic follow-up was done 15 days, 3 and 6 months after surgery.

## RESULTS

Out of the 37 patients who underwent surgical intervention, only 33 were taken in this study (PCTR). Among the rest three underwent tracheal resection and anastomosis and one underwent balloon dilatation (Table 1).

Of the 33 patients, 26 were males (78.78%) and 7 females (21.21%). The average age of patients was 34 (range 19–49).

The leading cause of stenosis was prolonged orotracheal intubation. Of the 37 patients in the study, 24 had a history of prolonged intubation and tracheotomy. Cranial trauma secondary to road traffic accidents was a predominant cause of prolonged intubation in the majority of the patients (Table 2).

The adopted Myer-Cotton classification<sup>2</sup> was used to evaluate the stenosis. Among the study sample, 30.1% ( $n = 16$ ) was class I, 45.28% ( $n = 24$ ) was class II, 24.52% was class III ( $n = 13$ ) (Table 3).

All patients who underwent surgery were kept intubated in postsurgical intensive care unit (ICU) for a period of 24 hours. Ninety-seven percent of patients were extubated after 24 hours successfully. The remaining patients were extubated

after 48 hours. After extubation, all patients were found to be asymptomatic. Among the total study sample, 25% ( $n = 8$ ) presented with complications. The most common complication seen postoperatively in patients was surgical emphysema (60%,  $n = 5$ ). T-tube blockage and T-tube displacement were the other complications seen in the patients. Postoperatively patients were reviewed 15 days, 3 months, and 6 months after surgery. Among them, 97% ( $n = 32$ ) had successful decannulation after 6 weeks postoperatively. One patient remained with the T-tube.

## DISCUSSION

Laryngotracheal stenosis is one of the most challenging pathological conditions in the field of otolaryngology bringing forth a plethora of physiological anomalies that require a multidisciplinary approach<sup>3</sup> in a tertiary setup. In the retrospective study conducted at our institute, the majority of the patient indicated for surgical intervention had a history of prolonged orotracheal intubation or tracheotomies. Laryngotracheal stenosis most frequently occurs secondary to prolonged intubation.<sup>4</sup> Although the rates tend to decrease with the use of endotracheal tubes with low pressure, stenosis is still a major problem in ICUs. Tracheal stenosis mostly develops around the cuff of the tube.<sup>5</sup> The incidence of stenosis after tracheostomy or laryngotracheal intubation ranges from 0.6 to 21%.<sup>5</sup> Intubation duration in our study group ranged from 14 to 21 days. There is no exact evidence about the timing of tracheostomy for intubated patients. Most authors who work in laryngeal reconstruction agree that 7 to 10 days of intubation is enough for laryngotracheal injury.<sup>6</sup> In our hospital setting, the mean was 8 days. A clinical analysis of such patients brought us to the conclusion that tracheostomies conducted in the appropriate anatomical location with subsequent monitoring of cuff pressure develop LTS less commonly.<sup>5</sup> Among the various arsenal in modern medicine in dealing with LTS-like endoscopic dilatation, LASER, and stent; PCTR is an effective surgical method with a high decannulation rate. Ninety-seven percent of patients observed in our study had successful decannulation. Endoscopic treatment may be less morbid and offers the patient less total operative and anesthesia time. These same factors may be one reason why we found endoscopic procedures to have less success compared to open procedures. Patients with more comorbid conditions may not be able to tolerate longer anesthesia time or more invasive surgery would require an endoscopic approach.

Before the surgical intervention, it is important to ascertain the grade, site, and duration of stenosis. Patients with minor stenosis (grades I and II) can be endoscopically treated.<sup>7</sup> Conservative mode of management was applied in patients with no circumferential scarring ( $n = 20$ ). Timing for surgery is another important aspect.

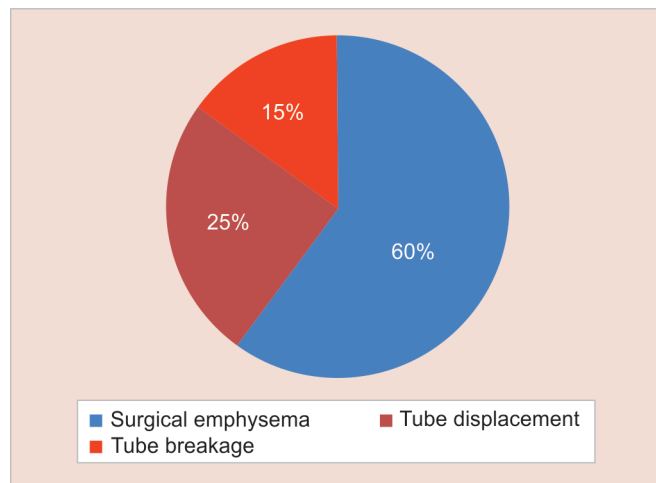


Fig. 1: Postoperative complication

Table 1: Showing incidence of severity

| Grade of stenosis | Cases (%) ( $n = 53$ ) |
|-------------------|------------------------|
| I                 | 30.1                   |
| II                | 45.28                  |
| III               | 24.52                  |
| IV                | 0                      |

Table 2: Showing distribution of incidence as per etiology

| Etiology   | Cases (%) ( $n = 53$ ) |
|------------|------------------------|
| Acquired   | 65                     |
| Mixed      | 26.6                   |
| Congenital | 8.4                    |

Table 3: Showing anatomical prevalence of pathology

| Site of stenosis              | Cases (%) ( $n = 53$ ) |
|-------------------------------|------------------------|
| Purely subglottic             | 77.35                  |
| Subglottic with upper trachea | 22.65                  |

Surgery should be delayed in clinically stable patients until inflammation has regressed and the scarring process has stabilized.<sup>6</sup> Most of our patients were extubated within the first 24 hours to allow the complete sealing of the suture and reduce granulation at the anastomosis site. In those patients in whom difficulties were foreseen, a T-tube placement and delayed decannulation appeared to be the appropriate option.<sup>3</sup> Despite the T-tubes' advantages, they may have also some disadvantages that may include obstruction by secretions and development of granulation tissue, both of which may lead to respiratory distress.<sup>3</sup> A similar retrospective analysis says granulation tissue formation is the most common complication postoperatively.<sup>3</sup> However, the careful placement of an absorbable submucosal suture embedded in healthy tissue seems to reduce its incidence.<sup>3</sup> Placing the anastomotic sutures through healthy tissues, extramucosally, also decreases the likelihood of the development of granulation tissue.<sup>1</sup>

One of the potential complications while doing a PCTR is the injury to the recurrent laryngeal nerve (RLN). Intraoperatively, this complication is averted by leaving aside the RLNs behind the cricothyroid joints by dissecting the anterior cricoid arch in a subperichondrial plane, the risk of injury is minimal, even in reoperations in which the nerves are embedded in scar tissue.<sup>2</sup>

In cases of T-tube breakage and T-tube displacement, patients were taken into the operation theatre (OT) and were promptly re-explored *via* bronchoscopic evaluation while maintaining a secure airway. Most commonly, it occurs within the first days or weeks after surgery but more remote events have been described. Excessive tension at the point of the anastomosis is usually at fault.<sup>8</sup>

Postoperative evaluation is critical in picking up early signs of complication such as dehiscence of anastomosis or restenosis. Regular flexible endoscopic evaluation of the airway is recommended for good patient outcomes.<sup>9</sup>

## CONCLUSION

Partial cricotracheal resection for treatment of posttraumatic upper tracheal and/or subglottic stenosis has a high success rate, especially in healthy patients without comorbidities.<sup>4</sup> Anastomotic complications are uncommon. Comorbid medical

condition,<sup>10</sup> lengthy resections,<sup>4</sup> young age (pediatric patients), and previous open airway intervention are associated with poor clinical outcome.<sup>4</sup> Stabilization of the patient's airway, evaluation with bronchoscopy, and use of a temporizing airway appliance are all important components of the management of airway complications.<sup>8</sup>

## REFERENCES

1. Har-El G, Shaha A, Chaudry R, et al. Resection of tracheal stenosis with end-to-end anastomosis. *Ann Otol Rhinol Laryngol* 1993;102(9):670–674. DOI: 10.1177/000348949310200904.
2. Myer 3rd CM, O'Connor DM, Cotton RT. Proposed grading system for subglottic stenosis based on endotracheal tube sizes. *Ann Otol Rhinol Laryngol* 1994;103(4 Pt 1):319–323. DOI: 10.1177/000348949410300410.
3. Marques P, Leal L, Spratley J, et al. Tracheal resection with primary anastomosis: 10 years experience. *Am J Otolaryngol* 2009;30(6):415–418. DOI: 10.1016/j.amjoto.2008.08.008.
4. El-Fattah AMA, Ebada HA, Amer HE, et al. Partial cricotracheal resection for severe upper tracheal stenosis: potential impacts on the outcome. *Auris Nasus Larynx* 2018;45(1):116–122. DOI: 10.1016/j.anl.2017.03.014.
5. Gozen ED, Yener M, Erdur ZB, et al. End-to-end anastomosis in the management of laryngotracheal defects. *J Laryngol Otol* 2017;131(5):447–454. DOI: 10.1017/S0022215117000378.
6. Pookamala S, Kumar R, Thakar A, et al. Laryngotracheal stenosis: clinical profile, surgical management and outcome. *Indian J Otolaryngol Head Neck Surg* 2014;66(Suppl 1):198–202. DOI: 10.1007/s12070-011-0424-2.
7. Sharpe DA, Dixon K, Moghissi K. Endoscopic laser treatment for tracheal obstruction. *Eur J Cardiothorac Surg* 1996;10(9):722–726. DOI: 10.1016/S1010-7940(96)80331-9.
8. Auchincloss HG, Wright CD. Complications after tracheal resection and reconstruction: prevention and treatment. *J Thorac Dis* 2016;8(Suppl 2):S160–S167.
9. Piazza C, Del Bon F, Paderno A, et al. Complications after tracheal and cricotracheal resection and anastomosis for inflammatory and neoplastic stenoses. *Ann Otol Rhinol Laryngol* 2014;123(11):798–804. DOI: 10.1177/0003489414538764.
10. Monnier P, Lang F, Savary M. Partial cricotracheal resection for severe pediatric subglottic stenosis: update of the lausanne experience. *Ann Otol Rhinol Laryngol* 1998;107(11 Pt 1):961–968. DOI: 10.1177/000348949810701111.