

CASE REPORT

First Reported Case of Giant Lipoma in a Child Involving Both Triangles of Neck

Keshav Gupta¹, Gaurav Kumar², Shilpa Tomar³

Received on: 04 April 2022; Accepted on: 05 September 2023; Published on: xx xx xxxxxx

ABSTRACT

Aim: Pediatric lipomas of the head and neck are rare to find and generally seen as isolated case reports. Here, we report an extremely rare type of giant childhood neck lipoma.

Background: Lipomas are a group of benign tumors formed due to abnormal and excessive proliferation of adipose tissue. They are most common in the age-group of 40–60 years. They are rare in the pediatric age-group and rarely occur under the age of 10 years.

Case description: A 100 mm × 80 mm × 80 mm, 1011-gm lipoma involving both anterior and posterior triangles of neck with attachments to mastoid process, medial and lateral pterygoids (base of skull), platysma, substance of submandibular gland, pretracheal fascia, and branches of external carotid (posterior auricular artery, occipital artery, and ascending pharyngeal artery) was removed from neck of an 8-year-old pediatric patient. Posterior auricular, occipital, and ascending pharyngeal arteries had taken an aberrant route because of the huge mass, and the ascending pharyngeal artery was forming its inferior boundary. The nasopharynx and the entire viscera of the neck were pushed to one side. The mass was adherent to the submandibular gland and in close relation with the lingual nerve.

Conclusion: This is the first case report of giant lipoma of the neck in a pediatric patient which involved both anterior and posterior triangles. This is the largest neck lipoma reported to date in a child.

Clinical significance: Excision of a large neck lipoma should be planned after imaging studies and in a fully equipped operation theater preferably in general anesthesia.

Keywords: Case report, Child, Giant, Largest, Lipoma.

Otorhinolaryngology Clinics: An International Journal (2023); 10.5005/jp-journals-10003-1463

BACKGROUND

A 100 mm × 80 mm × 80 mm, 1011-gm lipoma involving both anterior and posterior triangles of neck with attachments to mastoid process, medial and lateral pterygoids (base of skull), platysma, substance of submandibular gland, pretracheal fascia, and branches of external carotid (posterior auricular artery, occipital artery, and ascending pharyngeal artery) was removed from neck of 8-year-old pediatric male patient (Fig. 1). Posterior auricular, occipital, and ascending pharyngeal arteries had taken an aberrant route because of the huge mass, and the ascending pharyngeal artery was forming

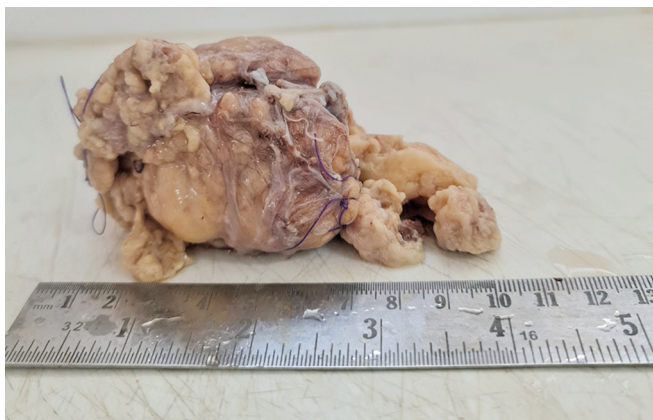

Fig. 1: A 10 cm × 8 cm × 8 cm lipoma (image taken after formalin fixation)

^{1,2}Department of ENT and Head & Neck Surgery, GS Medical College & Hospital, Hapur, Uttar Pradesh, India

³Department of Pathology, GS Medical College & Hospital, Hapur, Uttar Pradesh, India

Corresponding Author: Keshav Gupta, Department of ENT and Head & Neck Surgery, GS Medical College & Hospital, Hapur, Uttar Pradesh, India, Phone: +91 9518842606, e-mail: keshavpawangarg@gmail.com

How to cite this article: Gupta K, Kumar G, Tomar S. First Reported Case of Giant Lipoma in a Child Involving Both Triangles of Neck. *Int J Otorhinolaryngol Clin* 2023;x(x):xx-xx.

Source of support: Nil

Conflict of interest: None

its inferior boundary. The nasopharynx and the entire viscera of the neck were pushed to one side. The mass was adherent to the submandibular gland and in close relation with the lingual nerve. The size, location, and age-group in which lipoma was found make it unique and reportable (Fig. 2).

INTRODUCTION AND REVIEW OF LITERATURE

Lipomas are a group of benign tumors formed due to abnormal and excessive proliferation of adipose tissue.¹ They are most common in the age-group of 40–60 years.² They are rare in the pediatric age-group and rarely occur under the age of 10 years.³ They are more common in obese individuals.⁴ They are commonly reported from the trunk and limb region (Fig. 3). Only 13–15% of lipomas have been reported from the head and neck region.⁵ A lipoma that is more

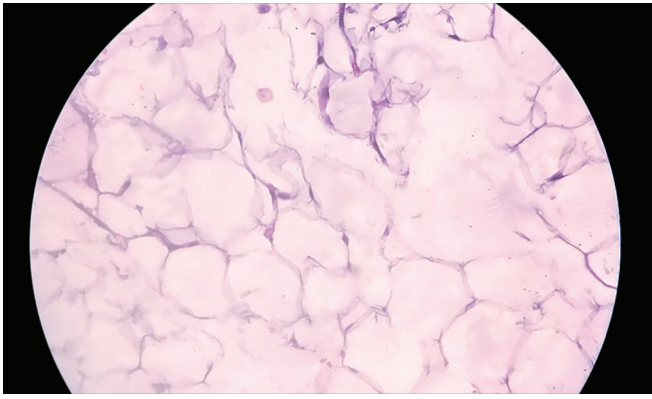


Fig. 2: Excised tissue seen in 100x magnification under microscope confirming the presence of lipoma

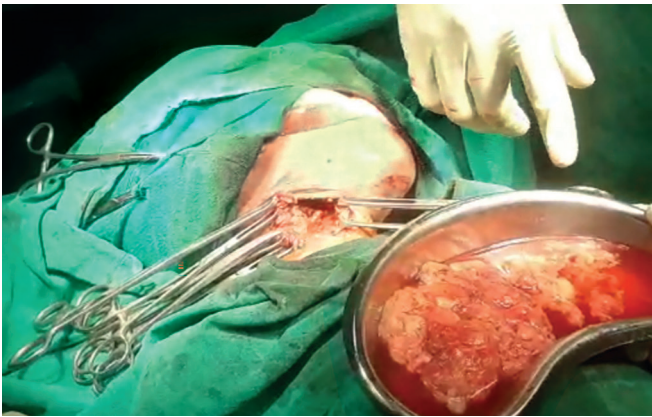


Fig. 3 : Intraoperative picture showing excised lipoma filling the large kidney tray

than or equal to 10 cm in maximum dimension or is more than or equal to 1 kg in weight is said to be a giant lipoma.⁶ Lipomas can be subcutaneous, intramuscular, intermuscular, and visceral or may arise from the carotid sheath.^{7,8} Most of them are seen in the posterior neck.⁹ Less than 13% are seen in the anterior neck.¹⁰ This is the first reported case of giant lipoma in the pediatric age-group involving both the neck triangles. Even though it was giant in size, it was completely reducible.

CASE DESCRIPTION

An 8-year-old male presented to our outpatient department with slow-growing neck swelling first noticed 3 years back. The swelling involved the right side of the neck and face. It was soft, non-tender, easily compressible, and appeared reducible as on pressing it easily squeezed into potential dead spaces of the neck. Ultrasonography neck, contrast-enhanced computerized tomography neck and fine needle aspiration cytology favored the presence of a lipoma (Fig. 4). Multiple aspirations into swelling did not yield anything. Excision was planned in general anesthesia. After general anesthesia was induced, a transverse 8-cm incision was given on the right side 2 fingerbreadths below the right angle of the mandible to avoid injury to the marginal mandibular nerve. The incision was deepened through the subcutaneous plane and platysma. The surface of the lipoma was reached in the subplatysmal plane, lipoma was carefully dissected from

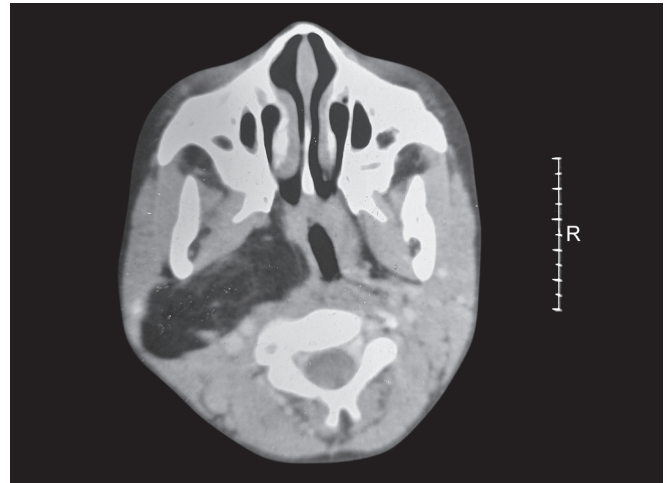


Fig. 4: Contrast-enhanced computerized tomography – axial section at the level of nasopharynx showing pushing of nasopharynx to the left

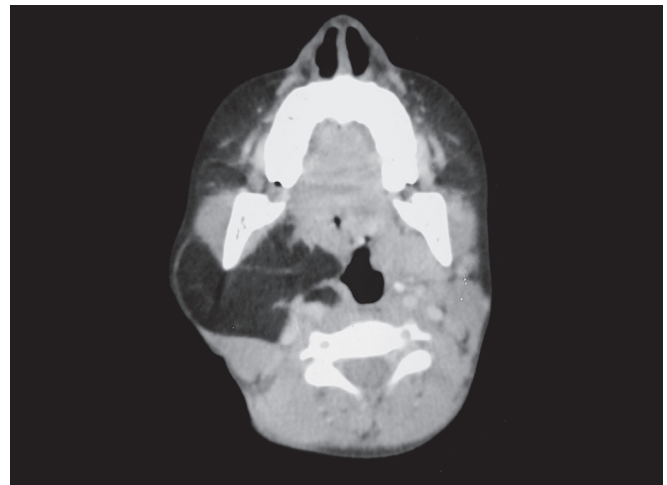


Fig. 5: Contrast-enhanced computerized tomography – axial section at the level of oropharynx showing its huge dimensions forming a palpable swelling in lower face and whole of neck on right side

surrounding structures. It had attachments to the mastoid process, sphenoid process, and petrous, and squamous part of the temporal bone. It was intermingling into the substance of the submandibular gland and carotid sheath. It was carefully dissected from branches of the external carotid artery and from the substance of the right submandibular gland. The cavity was washed with Betadine and tissue was sent for histopathology. A suction drain was put and the incision was closed in three layers (Figs 5 and 6).

DISCUSSION

During development, various molecular triggers can lead to uncontrolled division of adipose tissue present in deep fascia and salivary glands to form giant lipomas.² This particular lipoma was very yielding, entered the deep spaces of the neck, and disappeared completely on applying pressure as it was completely pushed into deep spaces of the neck. Its boundaries were traced to the base of the skull, salivary glands, and carotid sheath. It was in intimate

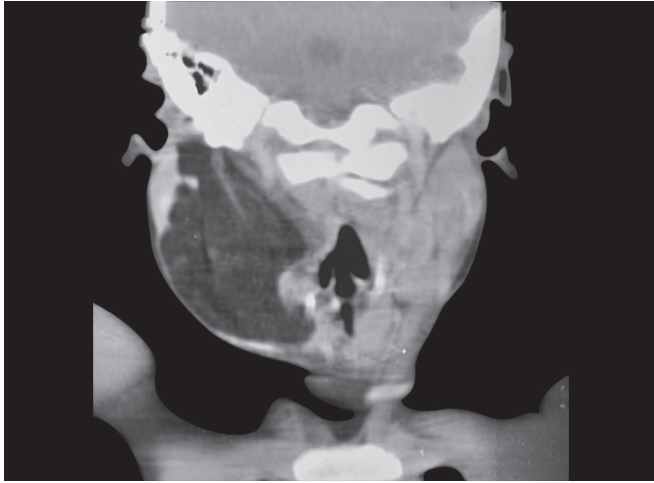


Fig. 6: Contrast-enhanced computerized tomography – coronal section showing a huge mass pushing entire neck viscera to the opposite side

relation to three branches of the external carotid artery. It involved both anterior and posterior triangles. It was safely excised without causing any vessel and nerve injury by meticulous dissection. Such lipomas can spread to any extent. The extent must be confirmed by imaging before planning surgery. Any injury to the external carotid or its branches is invariably fatal. The excision of a deep lipoma must be planned in a modern operation theater (OT) in general anesthesia. Cautery should be kept available. There is a case report where the carotid artery was injured during lipoma excision and carotid grafting was needed.¹¹

CONCLUSION

This is the first case report of giant lipoma of the neck in a pediatric patient which involved both the neck triangles. This is probably the largest neck lipoma reported to date in a child.

ORCID

Keshav Gupta  <https://orcid.org/0000-0003-2097-7436>

REFERENCES

1. Rico F, Hoang D, Lung J, et al. Substernocleidomastoid muscle neck lipoma: An isolated case report. *Case Reports in Surgery* 2019;2019:4936357. DOI: 10.1155/2019/4936357.
2. Brenn T. Neoplasms of subcutaneous fat. In: Goldsmith LA, Katz SI, Gilchrist BA, Paller AS, Leffell DJ, Wolff K. editors. *Fitzpatrick's Dermatology in General Medicine*, 8th edition. New York: McGraw Hill; 2012.
3. Tayeh C, Mneimneh S, El-Masri R, et al. Giant mesenteric lipoma: A case report and a review of the literature. *J Pediatr Surg Case Rep* 2015;3:166–170. DOI: 10.1016/j.epsc.2015.02.011.
4. Charifa A, Azmat CE, Badri T. Lipoma Pathology. In: StatPearls. Treasure Island (FL): StatPearls Publishing; 2022.
5. Deutsch PG, O'Connell J. Laryngeal lipoma: A rare cause of acute intermittent airway obstruction. *BMJ Case Reports* 2016;2016:bcr2016215506. DOI: 10.1136/bcr-2016-215506.
6. Eryilmaz MA, Yucel A, Yucel H, et al. Cervico–thoracic giant lipoma in a child. *Turk Arch Otorhinolaryngol* 2016;54(2):82–85. DOI: 10.5152/tao.2016.1620.
7. Parelkar S, Kapadnis S, Sanghvi B, et al. Carotid sheath lipoma: First case report in the English literature. *Ann R Coll Surg Engl* 2013;95(5):e77–e79. DOI: 10.1308/003588413X13629960045878.
8. Arif KN, Juneja R, Tandon S, et al. Giant lipoma of the neck: A case report. *MAMC J Med Sci* 2017;3:92–94. DOI: 10.4103/mamcjms.mamcjms_20_17.
9. El-Monem MHA, Gaafar AH, Magdy EA. Lipomas of the head and neck: Presentation variability and diagnostic work-up. *J Laryngol Otol* 2006;120(1):47–55. DOI: 10.1017/S0022215105004597.
10. Som PM, Scherl MP, Rao VM, et al. Rare presentations of ordinary lipomas of the head and neck: A review. *AJNR Am J Neuroradiol* 1986;7(4):657–664. PMID: 3088944.
11. Özcan C, Görür K, Talas D, et al. Intramuscular benign lipoma of the sternocleidomastoid muscle: A rare cause of neck mass. *Eur Arch Otorhinolaryngol* 2005;262(2):148–150. DOI: 10.1007/s00405-003-0732-6.