

Cutaneous Metastatic Deposits of Recto-sigmoid Adenocarcinoma after 7 Years of Surgery and Chemotherapy – A Rarity on Display

Manisha Sharma¹, Jyot Amrita², Mansimran Kaur³, Karamjit Singh Gill⁴

Received on: 17 November 2022; Accepted on: 20 February 2023; Published on: XX XXXX XXXX

ABSTRACT

Cutaneous metastasis of internal malignant neoplasms is rare and carries a poor prognosis. Colon adenocarcinomas cutaneous metastatic deposits are even rare amounting to approximately 2–4 %. A 53-year-old male patient presented with swelling in the lower back region with the clinical diagnosis of an infected sebaceous cyst. The histopathological examination of the excisional biopsy of the lesion revealed adenocarcinoma metastatic deposits in the dermis. The patient was found to be the treated case of recto-sigmoid carcinoma seven years back. Positron emission tomography (PET) scan of the patient suggested colonoscopy correlation to rule out local recurrence at the anastomotic site which was confirmed on the histopathology of the colonoscopy biopsy. So, all the patients diagnosed with any malignancy should be thoroughly examined for any cutaneous metastatic deposits.

Keywords: Adenocarcinoma, Biopsy, Cutaneous metastasis, Malignancy.

AMEI's Current Trends in Diagnosis & Treatment (2022): 10.5005/jp-journals-10055-0152

INTRODUCTION

Internal malignant neoplasms can spread through the skin in 0.7–9% of all malignant diseases, which is a rare sign of an advanced stage of the disease with a dismal prognosis. Colon adenocarcinomas cutaneous metastatic deposits are even rare amounting to approximately 2–4%.¹ Rarer still is this case study showcasing a known case of recto-sigmoid adenocarcinoma-moderately differentiated, since last 7 years, now diagnosed with cutaneous metastasis, post-surgery and post-chemotherapy. This case emphasizes how crucial it is to promptly investigate any new or developing skin lesions in patients who have a history of cancer. After the diagnosis survival of cutaneous metastasis ranges from 1 to 34 months.²

CASE REPORT

In June 2022, a 53-year-old male patient presented with an extensive new skin lesion on the lower left side of the back, and the clinical diagnosis of the infected sebaceous cyst was made. No fine needle aspiration cytology (FNAC) was done. The lesion was excised and sent for histopathology. On gross examination, a single firm soft tissue piece measuring 2.5 × 2.5 × 1.5 cm in size was received. The cut section through which was solid, and showed no pultaceous material. On microscopic examination, sections were lined by stratified squamous epithelium. The dermis showed the presence of tumor which was ill-circumscribed and arranged in papillary and glandular patterns at places (Fig. 1A). The individual tumor cells were large, round to oval in shape, and showed an increased N:C ratio with vesicular nuclei, prominent nucleoli, and a slight to moderate quantity of cytoplasm with some cells showing cytoplasmic vacuolations. Increased mitotic activity was noted in the sections examined (Figs 1B and C). Accordingly, the diagnosis of adenocarcinoma was made.

^{1,3,4}Department of Pathology, Sri Guru Ram Das Institute of Medical Sciences & Research, Amritsar, Punjab, India

²Department of Biochemistry, Sri Guru Ram Das Institute of Medical Sciences & Research, Amritsar, Punjab, India

Corresponding Author: Manisha Sharma, Department of Pathology, Sri Guru Ram Das Institute of Medical Sciences & Research, Amritsar, Punjab, India, Phone: +91 9876842942, e-mail: manishasalwan8025@gmail.com

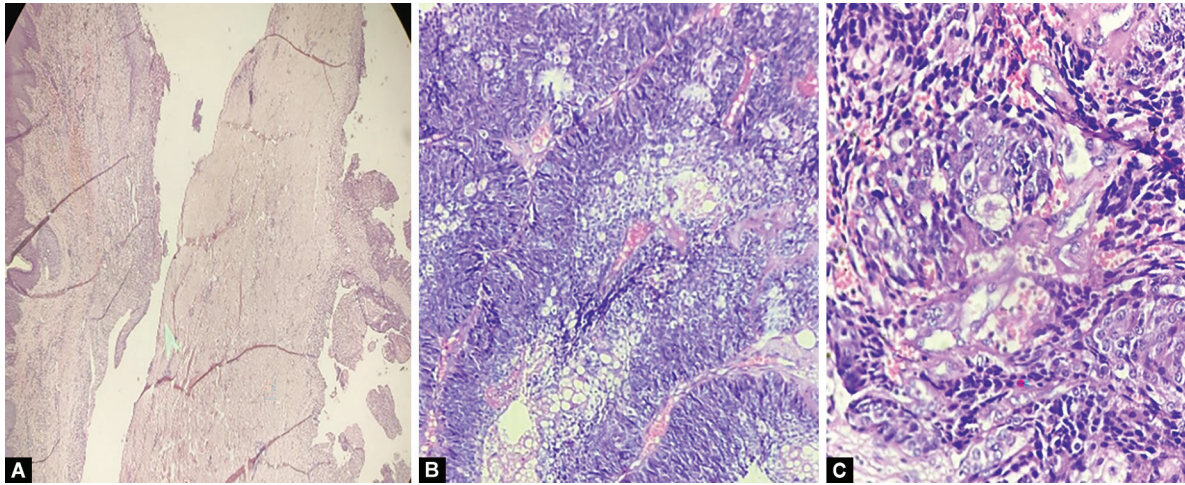
How to cite this article: Sharma M, Amrita J, Kaur M, et al. Cutaneous Metastatic Deposits of Recto-sigmoid Adenocarcinoma after 7 Years of Surgery and Chemotherapy – A Rarity on Display. AMEI's Curr Trends Diagn Treat 2022;x(x):xx–xx.

Source of support: Nil

Conflict of interest: None

Patient consent statement: The author(s) have obtained written informed consent from the patient for publication of the case report details and related images.

On tracing the clinical history of the patient, it was found that in the year 2015, this patient presented with the chief complaints of bleeding per rectum along with constipation, abdominal pain, and weight loss in the last 3–4 months. His medical history included hypertension which was controlled pharmacologically. A colonoscopy of the patient revealed an ulcero-proliferative mass seen involving the mid to distal rectum causing mild narrowing. Microscopic examination of the biopsy from the growth revealed adenocarcinoma-moderately differentiated. Following this low anterior resection (LAR) was done and two cycles of chemotherapy with Oxaliplatin, 5-FU, and Leucovorin were given. Repeated computed tomography (CT) scans showed no evidence of any recurrent or residual mass lesion.



Figs 1A to C: (A) Cutaneous metastasis in lower back region from adenocarcinoma rectosigmoid junction (H and E, 40X); (B) Adenocarcinoma arranged in papillary and glandular pattern (H and E, 100X); (C) Metastatic adenocarcinoma involving the dermis (H and E, 400X)

Consequently, the diagnosis of cutaneous-metastatic deposits of adenocarcinoma was made. On further investigations, a PET scan of the patient suggested colonoscopy correlation to rule out local recurrence at the anastomotic site as there was seen diffuse metabolic activity in the rectosigmoid junction. No metastatic deposits were seen in other internal organs. On colonoscopy and biopsy, the recurrence of the lesion was confirmed. The patient was started with chemotherapy after diagnosis of cutaneous metastasis.

DISCUSSION

Cutaneous metastasis from any internal organ malignancy is uncommon. Mostly tumors present with metastatic deposits at other visceral sites such as the liver and lung. Despite the rarity of the case, new or evolving skin lesions must raise suspicion for the presence of cutaneous metastatic deposits from internal organ malignancy. Clinicians should be cautious while treating patients with internal carcinomas. They should search for skin lesions even after a long asymptomatic period, really focusing on all skin nodules, non-healing ulcers, and tenacious indurate erythema. In these cases, cutaneous metastasis can present with different morphologies. Nodules and cutaneous growths are the most incessant structures mirroring aggravation like cellulitis and, surprisingly, epidermal blisters also.^{3,4} The other forms of presentations portraying the literature can be blisters, ulcers, alopecia plaques, and lesions resembling herpes-zoster, neurofibromas, annular erythema, condylomas and verrucous lesions.⁵ Taking into account that skin metastasis develop close to the primary lesion in the cases of extensive nodal involvement, pathophysiology is a mixture of intravascular and lymphatic diffusion, different methods of spread could be direct extension or implantation during the medical procedure.⁶

Various studies conducted revealed that the cutaneous metastasis may precede metastasis to other visceral organs and may present as the first clinical symptom of malignancy.⁷ Cutaneous metastasis carry an even poorer prognosis if associated with other internal organs metastasis. The survival period after diagnosis of cutaneous metastasis varies from one month to thirty-four months with an average of eighteen months in patients

with colorectal cancer.² In cases where cutaneous metastasis is isolated and not associated with visceral metastasis carry a better prognosis. Wide local excision and reconstruction can be considered.^{8,9} Clinicians should hold the responsibility to thoroughly examine the patient for any cutaneous lesion and to educate the patients to examine all regions of their skin to perceive the indications of cutaneous metastasis and to make a suitable move in time.

ORCID

Jyot Amrita  <https://orcid.org/0000-0002-3216-3838>

CONCLUSION

It is immensely important that patients with visceral malignancy must make frequent visits to the dermatology outpatient department (OPD) as cutaneous metastasis signifies disseminated disease, which warrants a thorough metastatic workup. Patient training assumes a significant part in this early and timely recognition of metastatic deposits on the skin which can intensely alter the treatment and prognosis in these cases with immediate palliative chemotherapy and radiotherapy along with surgical resection of the lesion.

REFERENCES

1. Bittencourt MD, Imbiriba AA, Oliveira OA, et al. Cutaneous metastasis of colorectal cancer. *An Bras Dermatol* 2018;93(6):884–886. DOI: 10.1590/abd1806-4841.20187610.
2. Nesseris I, Tsamakos C, Gregoriou S, et al. Cutaneous metastasis of colon adenocarcinoma: Case report and review of the literature. *An Bras Dermatol* 2013;88(6):56–58. DOI: 10.1590/abd1806-4841.20132441.
3. Saeed S, Keehn CA, Morgan MB. Cutaneous metastasis: A clinical, pathological, and immunohistochemical appraisal. *J Cutan Pathol* 2004;31(6):419–430. DOI: 10.1111/j.0303-6987.2004.00207.x.
4. Lookingbill DP, Spangler N, Helm KF. Cutaneous metastases in patients with metastatic carcinoma: A retrospective study of 4020 patients. *J Am Acad Dermatol* 1993;29(2pt1):228–236. DOI: 10.1016/0190-9622(93)70173-q.
5. Ocampo-Candiani J, Castrejón-Pérez AD, Ayala-Cortés AS, et al. Cutaneous colon metastases mimicking elephantiasis

- verrucosa nostra. *Am J Med Sci* 2015;350(6):517–518. DOI: 10.1097/MAJ.0000000000000595.
6. Damin DC, Lazzaron AR, Tarta C, et al. Massive zosteriform cutaneous metastasis from rectal carcinoma. *Tech Coloproctol* 2003;7(2): 105–107. DOI: 10.1007/s10151-003-0019-3.
 7. Tan KY, Ho KS, Lai JH. Cutaneous and subcutaneous metastases of adenocarcinoma of the colon and rectum. *Ann Acad Med Singap* 2006;35(8): 585–587. PMID: 17006588.
 8. Kilickap S, Aksoy S, Dinçer M, et al. Cutaneous metastases of signet cell carcinoma of the rectum without accompanying visceral involvement. *South Med J* 2006;99(10):1137–1139. DOI: 10.1097/01.smj.0000221633.71021.ac.
 9. Dehal A, Patel S, Kim S, et al. Cutaneous metastasis of rectal cancer: A case report and literature review. *Perm J* 2016;20(1):74–78. DOI: 10.7812/TPP/15-078.