

Anesthesia Management of Jehovah's Witness Undergoing Major Abdominal Surgery

Trupti S Pethkar¹, Minoti K Kamdar², Vaishali V Joshi³

Received on: 26 April 2023; Accepted on: 17 July 2023; Published on: xxxx

ABSTRACT

Aim and background: Jehovah's Witness (JW) religion is a proselytizing Christian movement. They have strong religious beliefs retrieved from a strictly literal interpretation of passages in the Bible forbidding the "eating" of blood as there is the fright of losing eternal life. They refuse to accept homologous or autologous whole blood and blood products, even in case of emergency, to prevent morbidity and mortality.

Case description: We discuss the successful use of cell saver in JW patients presenting with multiple fibroids and heavy bleeding undergoing total abdominal hysterectomy with bilateral salpingectomy with expected blood loss of 1.5–2 L under general anesthesia with epidural analgesia. Proper consent and preoperative planning with an experienced team is essential.

Conclusion: To work in the window of providing a bloodless surgery under the circumstances of the legal and ethical issues of JW is challenging. Proper planning is needed to handle the available limited options to manage intraoperative blood loss.

Clinical significance: Preoperative counseling to discuss and understand JW's religious beliefs and accordingly tailoring the anesthesia plan and surgical interventions is of legal importance.

Keywords: Autologous blood transfusion, Case report, Jehovah's Witness, Operative cell salvage.

Journal of Research and Innovation in Anesthesia (2023): 10.5005/jp-journals-10049-2034

INTRODUCTION

Jehovah's Witness (JW) is a religious group with more than eight million members around the world. It is represented by a Christian denomination and was introduced by the International Bible Students Association in 1872 in Pittsburgh. Their wish to set up the earth as God's kingdom is based on the sacredness of blood and its nonacceptance in the form of intravenous (IV) transfusions leads to challenges and ethical dilemmas for perioperative physicians. This is governed by a body in Brooklyn, New York.^{1,2} We hereby report a case of JW with multiple uterine fibroids posted for major surgery with expected blood loss of 2 L managed with planned cell saver. Proper counseling and consent, preoperative planning, preparation, and an experienced team are the pillars of an uncomplicated outcome. The anesthetic management is discussed and the learning points are highlighted.

CASE DESCRIPTION

Preoperative Preparation

A 46-year-old JW with no known comorbidities was posted for open total abdominal hysterectomy with bilateral salpingectomy. She had heavy menstrual bleeding for 5 years with increased urinary frequency and pressure symptoms. Magnetic resonance imaging showed multiple intramurals, submucosal, and subserosal fibroids, with the largest being 11 × 10 × 12.8 cm. The patient had a preoperative hemoglobin

^{1,2}Department of Anaesthesiology, Kokilaben Dhirubhai Ambani Hospital, Mumbai, Maharashtra, India

³Department of Gynaecology & Obstetrics, Kokilaben Dhirubhai Ambani Hospital, Mumbai, Maharashtra, India

Corresponding Author: Trupti S Pethkar, Department of Anaesthesiology, Kokilaben Dhirubhai Ambani Hospital, Mumbai, Maharashtra, India, Phone: +91 9699041444, e-mail: truptipethkar@yahoo.co.in

How to cite this article: Pethkar TS, Kamdar MK, Joshi VV. Anesthesia Management of Jehovah's Witness Undergoing Major Abdominal Surgery. *J Res and Innov Anesth* 2023;https://doi.org/10.5005/jp-journals-10049-2034.

Source of support: Nil

Conflict of interest: None

Patient consent statement: The author(s) have obtained written informed consent from the patient for publication of the case report details and related images.

of 12.5 gm/dL and normal coagulation profile, bleeding time, clotting time, and other routine investigations, including electrocardiogram and echo. The patient had a past surgical history of laparoscopic cholecystectomy under general anesthesia with no blood transfusion. The patient tried taking oral contraceptives and tranexamic acid for her heavy periods, but as they were not helpful, she was given double oral iron supplements (ferrous ascorbate, folic acid, methylcobalamin

suspension) for the last 2 months in order to increase her hemoglobin. She was advised to postpone the surgery by 2 months to have postoperative hemoglobin around 12 gm/dL as the anticipated blood loss was 1.5–2 L. She was also advised to take Zoladex (gonadotropin-releasing hormone agonist) to shrink the fibroids to reduce the blood loss but this was declined by the patient due to cost and social reasons. A special written informed consent was taken under "Health Care Proxy-Massachusetts General Law chapter 201D" after explaining the additional risk of blood refusal, to set forth her treatment instructions and to appoint a healthcare agent in case of her incapacity as per Acts 15:28:29. This states that no transfusions of whole blood red cells, white cells, platelets, or plasma are to be given to her under any circumstances, even if healthcare providers believe that such is necessary to preserve her life. However, she consents to autotransfusion by intraoperative blood salvage technique. She also consents to not wanting to prolong her life if, to a reasonable degree of medical certainty, her situation is hopeless. She didn't give authority to anyone to disregard or override her instructions set forth herein but at the same time, she appointed a healthcare personnel to make healthcare decisions for her who has full power and authority to consent or refuse the treatment on her behalf, to consult with her doctors, receive copies of her medical records and take legal action to ensure that her wishes are honored. She also appoints an alternate agent herein to serve with the latter in case the first one is unavailable or unwilling to serve. Separate anesthesia and surgical consents, along with high-risk consent as per hospital protocol, are taken due to the patient's personal choices.

Perioperative Management

The anesthesia plan was to put a lumbar epidural catheter followed by general anesthesia. A cell salvage machine (Fig. 1) was set up by priming it with a liter of saline containing 30,000 U of heparin for autotransfusion, which would allow in-line circulation with no loss of contact with the patient.

The patient was shifted to the operating room after adequate fasting. Routine monitoring and 20G IV access were secured. She was premedicated with glycopyrrolate. An

18G epidural catheter was inserted in the L3–L4 intervertebral space in the sitting position. General anesthesia was then induced and endotracheal intubation was done after preoxygenation with propofol and atracurium and maintained on sevoflurane with air oxygen with atracurium infusion. A dedicated 18G IV cannula was secured to return the cell-saved red blood cells (RBCs). Postinduction, epidural infusion of 0.1% ropivacaine with 2 µg/mL fentanyl was started at 12 mL/hour. Tranexamic acid 1 gm was given preincision. Intraoperatively, the vitals were maintained in the normal range. She was covered with a warming blanket in the thoracic region, arms, and lower limbs to prevent hypothermia. A specimen weighing 2.5 kg (Fig. 2) was delivered through the midline incision from infraumbilicus to pubic symphysis in 20° Trendelenburg position.

A total of 880 mL blood of hematocrit 11% was received by cell salvage machine, anticoagulated, centrifuged, and washed and 315 mL of filtered packed RBCs with hematocrit 40% were reinfused to the patient (Fig. 3).

Paracetamol with antiemetic prophylaxis was given. The patient was extubated after adequate reversal. Total operating time was 2 hours and 15 minutes. Total blood loss was 1100 mL, and urine output was 600 mL replaced by 2500 mL crystalloids. She was shifted to the wards 2 hours

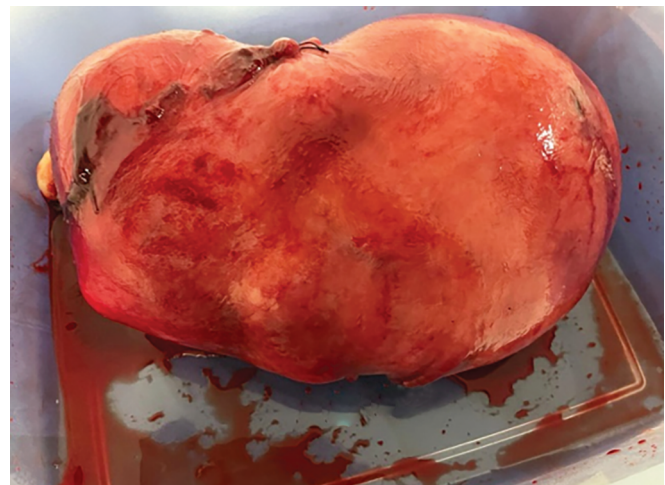


Fig. 2: Specimen of total hysterectomy with bilateral salpingectomy

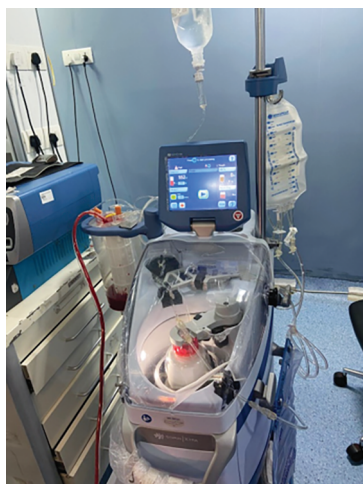

Fig. 1: Cell salvage machine

Patient ID:

Case # 317

Date 2023/03/04

Printer

▽

Add Bowl Tally

Add Alarms & Mods

Send Output

Bowl (#)	Fluid In (ml)	Hct In (%)	RBCs (ml)	HCT Out (%)	Supernatant (↓ %)	Waste line
2	380	9	160	37	91	●
1	500	12	157	46	91	●
---	---	---	---	---	---	---
Totals:	880	11	317	40	---	---

ATS

SEQ

Past Cases

Fig. 3: Screen view of cell salvage machine

postobservation in the postanesthesia care unit with the same epidural infusion at 7 mL/hour with a visual analog scale score of 3/10. She was closely monitored in the ward. Postoperative hemoglobin was 10.2 gm/dL on day 3. The epidural catheter was removed on postoperative day 2, and the patient was discharged on postoperative day 3. Her stay in the ward was uneventful.

DISCUSSION

Jehovah's Witness (JW) believes that human blood is sacred and a potential vector for sin, whereas Christ's blood is Holy and is the only blood that can redeem them. JW separates the blood into four major components, namely red cells, white cells, platelets, and plasma, which must not be "consumed" in any circumstance because they may irreversibly compromise their souls. Acceptable modes of therapies may vary from patient to patient. An elective surgery on a JW patient should proceed only if the center has the facility to address all elements of patient management. Preoperatively phlebotomy should be restricted to minimum selective essential diagnostic tests to evaluate bleeding and coagulation disorders. Patients should be optimized by enhancing hemoglobin and RBC production with iron, vitamin B₁₂, folate, ascorbic acid, and recombinant human erythropoietin in anemic patients for elective surgeries. Our patient was on an oral combination of ferrous ascorbate folic acid and methylcobalamin for the last 2 months. Patients need to be counseled regarding the acceptable modes of therapy and consequences. The alternatives include transfusion of RBC fractions like hemoglobin/hemopure, white blood cells fractions like interferons/interleukins, plasma fractions like immunoglobulins, albumin, cryoprecipitate, clotting factors, and platelet fractions like platelet factor IV. The different modes are transfusion acute hypervolemic hemodilution, intraoperative cell salvage, cardiopulmonary bypass, and extracorporeal membrane oxygenation.¹ Written informed consent³ and advanced directive with thorough documentation regarding the worst scenario were taken from the patient. This has medicolegal implications. The acceptance of autologous donation and reinfusion is an individual's decision based on the maintenance of the continuity with the circulatory system at all times. Allogenic whole blood or blood products were not acceptable to our patient; however, autologous blood transfusion was acceptable. The potential complications following the use of cell savers, such as electrolyte imbalance, air embolism, pyrexia with rigors, infection, fat embolism, microaggregates causing microembolism, and salvaged blood syndrome, need thorough discussion.⁴ Minimization of blood loss is of utmost importance. Being an elective surgery, preoperative hematinic and other available modes were offered to the patient. Careful positioning, regional techniques, and avoidance of high intrathoracic pressures and hypercapnia, can decrease venous congestion and

venous ooze.⁵ Intraoperative pain management, essential to prevent tachycardia and hypertension to reduce blood loss, was well managed with an epidural infusion. The mean arterial pressure was maintained between 60 and 65 mm Hg. Hypothermia-induced coagulopathy and blood loss were avoided by forced air warmer with a blanket and IV fluid warmer. Tranexamic acid, along with the use of a cell saver, is recommended for all surgical procedures if the expected blood loss is >500 mL.⁶ Two wide-bore IV accesses were secured in anticipation of fluid management. Adequate fluid replacements with crystalloids and autotransfused blood were done. Optimization of anemia tolerance needs to be done in JW by maximizing oxygen delivery by intubation, ventilation, and cardiopulmonary bypass and by minimizing oxygen uptake and metabolic demand by sedation, paralysis, and prevention of shock. Our patient was sedated, paralyzed, intubated, and ventilated to maintain partial pressure of carbon dioxide 35–40 mm Hg; adequate fluid replacement was done. Large-bore IV cannulas were secured for fluid resuscitation, blood transfusion, and inotropes if required. Postoperatively, adequate analgesia and monitoring of the vitals are recommended with oxygen supplementation. It can detect the bleeding early and gives time for corrective measures. A postoperative complete blood count needs to be done, and further management has to be planned accordingly.

CONCLUSION

Knowledge of JW's beliefs regarding blood transfusion is essential as it raises various ethical and legal issues.⁴ In order to honor their religious beliefs, during the intraoperative management of the major surgeries, special consent is needed after proper counseling. Blood-free major surgery in Jehovah's presents a challenge to an anesthetic and surgical team. A perfect plan to avoid and manage major blood loss starts from the preoperative period. Techniques learned from treating them may prove beneficial to all patients undergoing major surgeries. Though there are no fixed protocols, successful care requires a holistic approach focusing on preoptimization, referral to an appropriate perioperative JW environment for surgery, and perioperative blood conservation. In spite of the known complications and the cost involved in the use of the cell saver, it provides an excellent option for major surgeries in JW patients. Recently, continuous autotransfusion devices CAT-smart and CATS-plus have been introduced with better results.

Clinical Significance

The strong religious beliefs of JW limit the clinician with few options to handle various medical, anesthetic, and surgical challenges in order to avoid the circumstances which culminate in the need for blood and blood products. To respect them, proper preoperative counseling to explain the consent, the need for different substitutes of the blood components, and other options play a major role.

ORCID

Trupti S Pethkar  <https://orcid.org/0009-0006-6079-2064>

REFERENCES

1. Lawson T, Ralph C. Perioperative Jehovah's Witnesses: a review. *Br J Anaesth* 2015;115(5):676–687. DOI: 10.1093/bja/aev161
2. Lin ES, Kaye AD, Baluch AR. Preanesthetic assessment of the Jehovah's Witness Patient. *Ochsner J* 2012;12(1):61–69. PMID: 22438784.
3. Milligan LJ, Bellamy MC. Anaesthesia and critical care of Jehovah's Witnesses. *Contin Educ Anaesth Crit Care Pain* 2004;4(2):35–39. DOI: 10.1093/bjaceaccp/mkh012
4. Kuppurao L, Wee M. Perioperative cell salvage. *Contin Educ Anaesth Crit Care Pain* 2010;10(4):104–108. DOI: 10.1093/bjaceaccp/mkq017
5. Chand NK, Subramanya HB, Rao GV. Management of patients who refuse blood transfusion. *Indian J Anaesth* 2014;58(5):658–664. DOI: 10.4103/0019-5049.144680
6. Klein AA, Bailey CR, Charlton A, et al. Association of anaesthetists: anaesthesia and peri-operative care for Jehovah's Witnesses and patients who refuse blood. *Anaesthesia* 2019;74(1):74–82. DOI: 10.1111/anae.14441