

# Cervical Ligamentum Flavum Cyst Causing Myelopathy: A Case Report

Thomas J Kishen<sup>1</sup>, Prabhakar Sekar<sup>2</sup>

Received on: 03 January 2024; Accepted on: 05 February 2024; Published on: xxxx

## ABSTRACT

**Aims and background:** Symptomatic ligamentum flavum cysts in the cervical spine are an uncommon entity and can potentially cause neural compression, leading to radiculopathy and myelopathy. In this report, we discuss the clinical presentation, imaging findings, and management of a cervical ligamentum flavum cyst causing myelopathy in a 68-year-old gentleman.

**Case description:** A 68-year-old gentleman presented with progressive paresthesia and weakness of both upper limbs of 6 months duration, along with clumsiness of both hands and difficulty in walking. Magnetic resonance imaging (MRI) scan of the cervical spine showed a ventral midline ligamentum flavum causing cord compression and myelomalacia along with bilateral C3-C4 facet arthritis. The patient underwent a C3-C5 limited laminectomy, undercutting of the superior border of C6 lamina and C3-C6 lateral mass screw-based instrumented fusion with locally harvested autograft. At the 3-month follow-up, the gait, motor power, and sensations in all four limbs had returned to normal.

**Conclusion:** Ligamentum flavum cysts in the subaxial cervical spine are the result of spinal degeneration and have the potential to cause myelopathy. Surgical excision of the cyst and neural decompression with or without fusion is the treatment of choice for symptomatic cysts.

**Clinical significance:** Cervical ligamentum flavum cyst is an uncommon entity and can potentially cause myelopathy and/or radiculopathy. It is imperative to recognize this entity on imaging and correlate it with the symptoms. Surgical excision of the cyst, with or without fusion, is the treatment of choice.

**Keywords:** Case report, Cyst, Extradural, Laminectomy, Ligamentum flavum, Myelopathy.

*Journal of Orthopedics and Joint Surgery* (2024): 10.5005/jojs-10079-1147

## INTRODUCTION

Various intraspinal extradural cysts have been reported, including synovial cysts,<sup>1</sup> ganglion cysts of the ligamentum flavum,<sup>2-4</sup> posterior longitudinal ligament cyst,<sup>5</sup> and intervertebral disc cyst<sup>6</sup> each with its distinctive origin, location and histological features. Synovial cysts typically arise from the facet joints, contain clear fluid, and have a characteristic synovial lining.<sup>7</sup> Ganglion cysts, on the contrary, contain a gelatinous/viscous fluid without a distinct synovial lining.<sup>7</sup> Although these cysts, more common in the lumbar<sup>1,8-10</sup> than the cervical spine, differ in etiology, location, and histopathology, they have a similar clinical presentation and management.

Since ligamentum flavum cysts are seen predominantly in older people, myxoid degeneration of the ligamentum flavum is the proposed etiology of this condition.<sup>2</sup> By virtue of their space-occupying nature, these lesions can cause symptomatic neural compression leading to myelopathy (77%), radiculopathy (20%) or myeloradiculopathy (3%).<sup>7</sup> Surgical excision of the cyst and neural decompression to alleviate the compressive symptoms,<sup>1,11</sup> along with an instrumented fusion if deemed necessary, is the treatment of this condition.

This case report discusses the clinical presentation, imaging findings and management of a cervical ligamentum flavum cyst causing myelopathy.

## CASE DESCRIPTION

A 68-year-old gentleman presented with progressive paresthesia and weakness of both upper limbs of six months duration,

<sup>1,2</sup>Spine Care Centre, Manipal Hospital, Bengaluru, Karnataka, India

**Corresponding Author:** Thomas J Kishen, Spine Care Centre, Manipal Hospital, Bengaluru, Karnataka, India, Phone: +91 8025023334, e-mail: thomas.kishen@manipalhospitals.com

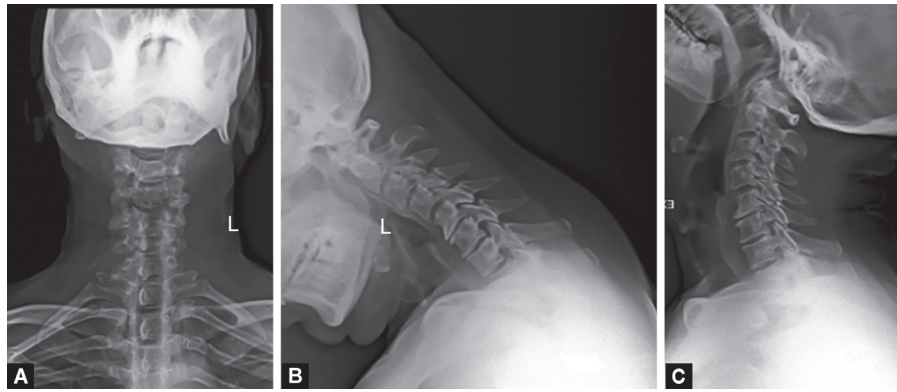
**How to cite this article:** Kishen TJ, Sekar P. Cervical Ligamentum Flavum Cyst Causing Myelopathy: A Case Report. *J Orth Joint Surg* 2024;https://doi.org/10.5005/jojs-10079-1147.

**Source of support:** Nil

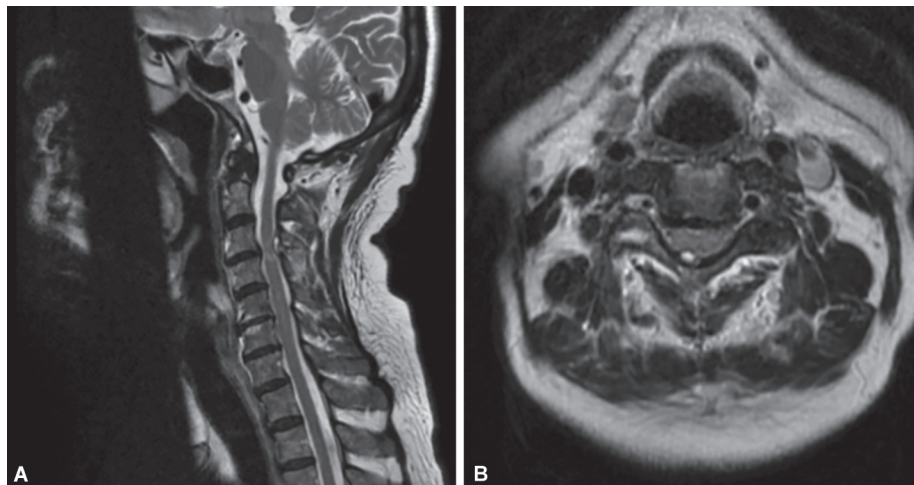
**Conflict of interest:** None

along with clumsiness of both hands and difficulty in walking of 20 days duration in the absence of any trauma. Bladder and bowel function was normal, and there were no constitutional symptoms. Physical examination revealed an unsteady gait with increased tone in both upper and lower limbs, shoulder abductor power was 3/5 bilaterally, and hand grip was weak bilaterally. Lower limb motor power was normal. Deep tendon reflexes were exaggerated in all four limbs with evidence of ankle clonus, positive Hoffman's and Babinski's sign bilaterally. Perianal sensations were normal, and distal pulses were well felt. The range of movements of the cervical and thoracolumbar spine was full and painless.

Plain radiographs (Fig. 1) of the cervical spine revealed degenerative changes in the cervical spine, and dynamic views showed grade I instability at the C3-C4 level. The cervical spine magnetic resonance imaging (MRI) scan (Fig. 2) showed a cystic fluid-filled lesion about 4 mm in maximum thickness arising from the ventral midline ligamentum flavum causing cord



**Figs 1A to C:** Plain radiograph of the cervical spine (anteroposterior, flexion, and extension) showing mild listhesis at C3-C4 level



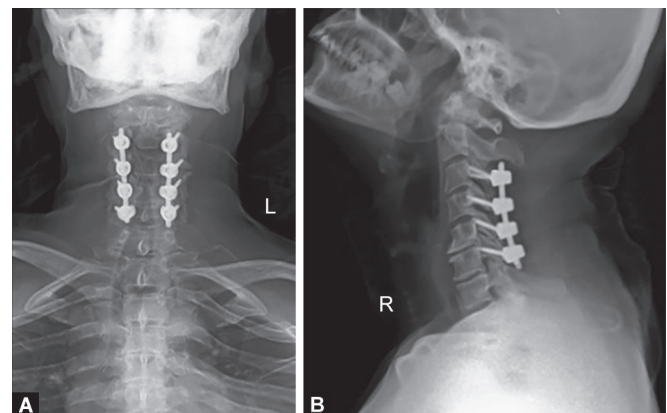
**Figs 2A and B:** The MRI scan of the cervical spine (sagittal and axial sections) showing a ligamentum flavum cyst causing cord compression and myelomalacia

compression and myelomalacia along with bilateral C3-C4 facet arthritis. Blood parameters were normal, with the exception of raised blood sugars and recently diagnosed ischemic heart disease.

In view of the upper motor neuron signs, clumsiness of hands and difficulty in walking resulting from cord compression and myelomalacia, a decompressive laminectomy was considered. An instrumented fusion was added to address the C3-C4 facet arthritis and instability. Subsequently, a C3-C5 limited laminectomy, undercutting of the superior border of C6 lamina and C3-C6 lateral mass screw-based instrumented fusion (Fig. 3) with locally harvested autograft was performed. The surgery was uneventful, and mobilization was permitted on the day after surgery. Significant improvement in the paresthesia in upper limbs was noticed soon after surgery. The gait, motor power and sensations in all four limbs had returned to normal in 3 months.

## DISCUSSION

Ligamentum flavum cysts in the cervical spine, first reported by Takana,<sup>4</sup> occur in the degenerated spines of older individuals. Alternative terminology includes "intraspinal cervical degenerative cyst,"<sup>12</sup> "degenerative intraspinal cyst,"<sup>7</sup> and "juxta-facet cysts."<sup>13</sup>



**Figs 3A and B:** Postoperative radiograph of the cervical spine (anteroposterior and lateral) showing the laminectomy and lateral mass screw fixation

In view of the difficulty in ascertaining whether the cyst is arising from the facet joint or ligamentum flavum, the term "degenerative intraspinal cyst" may be more appropriate to describe cysts arising from degenerated facet joints, ligaments, and disks.<sup>7</sup> The gelatinous content, lack of synovial lining, inclusion in the ligament

and noncommunication with the facet joint space and capsule differentiate ganglion cysts of the ligamentum flavum from facet synovial cysts.<sup>12</sup> Although the pathogenesis is not well understood, repetitive trauma to the ligamentum flavum in a degenerated spine leads to degeneration and replacement of the elastic fibers in the flavum with less flexible collagen fibers, which are prone to developing tears, myxoid degeneration, regional necrosis and, finally, microcystic changes which coalesce to form larger cysts is the proposed etiology.<sup>2,3</sup> The typical location of these cysts in the mobile sections of a degenerated spine further confirms this theory.<sup>2,12,14</sup> Segmental instability plays an aggravating role in the pathogenesis of ligamentum flavum cysts.<sup>1,8,10,12</sup> Cysts are commonly located laterally within the spinal canal due to the thin ligament and less resistance at the posterior recesses.<sup>12</sup> Larger cysts in the cervical can cause cord compression and myelopathy,<sup>4</sup> while laterally located small cysts can cause nerve root compression and radicular symptoms.

The cyst typically has a firm, fibroelastic wall containing a yellowish, thick gel-like substance.<sup>2</sup> Microscopically, the cyst wall has no lining, although it may contain calcium deposits along with hemorrhagic deposits and neovascularization in the adjacent ligamentum flavum.<sup>2</sup>

The MRI scan is the imaging modality of choice with ligamentum flavum cysts appearing as well-demarcated lesions, which are isointense on T1-weighted images and hyperintense on T2-weighted images with an enhancing cystic rim after administration of contrast.<sup>2,3,11</sup> In addition, dynamic radiographs of the cervical spine are useful for identifying instability and listhesis. The smooth, well-defined margins, absence of infiltrative characteristics and typical T1 and T2 magnetic resonance characteristics help to differentiate this lesion from other space-occupying lesions in the cervical spinal canal.<sup>2</sup>

The treatment of symptomatic ligamentum flavum cysts is surgical excision and neural decompression with or without instrumented fusion. Instrumentation is deemed necessary when wide exposure and multiple-level laminectomies are performed<sup>2</sup> and in the presence of painful degenerative changes and instability in the spine.<sup>1,8,10</sup> The results of surgical management of ligamentum flavum cysts have been reported to be uniformly good.<sup>3,4,9</sup>

In our patient with a midline ligamentum flavum cyst causing compressive myelopathy segmental instability and facet arthritis at C3-C4, we performed a C3-C5 limited laminectomy with cyst excision and C3-C6 instrumented fusion. Complete neurological recovery was reported at 3 months.

## CONCLUSION

Ligamentum flavum cysts in the subaxial cervical spine are the result of spinal degeneration and have the potential to cause myelopathy. Surgical excision of the cyst and neural decompression with or without fusion is the treatment of choice for symptomatic cysts.

## Clinical Significance

Cervical ligamentum flavum cyst is an uncommon entity and can potentially cause myelopathy and/or radiculopathy. It is imperative to recognize this entity on imaging and correlate it with the symptoms. Surgical excision of the cyst, along with or without fusion, is the treatment of choice.

## ORCID

Thomas J Kishen  <https://orcid.org/0000-0001-8467-5467>

Prabhakar Sekar  <https://orcid.org/0009-0009-6661-2628>

## REFERENCES

1. Howington JU, Connolly ES, Voorhies RM. Intraspinal synovial cysts: 10-year experience at the ochsner. *Clin J Neurosurg* 1999;91(Suppl 2):193–199. DOI: 10.3171/spi.1999.91.2.0193
2. Brotis AG, Kapsalaki EZ, Papadopoulos EK, et al. A cervical ligamentum flavum cyst in an 82-year-old woman presenting with spinal cord compression: a case report and review of the literature. *J Med Case Rep* 2012;6:92. DOI: 10.1186/1752-1947-6-92
3. Muzii VF, Tanganelli P, Signori G, et al. Ganglion cyst of the ligamentum flavum: a rare cause of cervical spinal cord compression. A case report. *J Neurol Neurosurg Psychiatry* 2010;81(8):940–941. DOI: 10.1136/jnnp.2008.169169
4. Takano Y, Homma T, Okumura H, et al. Ganglion cyst occurring in the ligamentum flavum of the cervical spine. *Spine* 1992;17(12):1531–1533. DOI: 10.1097/00007632-199212000-00020
5. Cho SM, Rhee WT, Lee SY, et al. Ganglion cyst of the posterior longitudinal ligament causing lumbar radiculopathy. *J Korean Neurosurg Soc* 2010;47(4):298–301. DOI: 10.3340/jkns.2010.47.4.298
6. Kishen TJ, Shetty AP, Rajasekaran S. Variant of a lumbar disc cyst in a 13-year-old girl: a case report. *J Orthop Surg (Hong Kong)* 2006;14(2):184–186. DOI: 10.1177/230949900601400215
7. Shima Y, Rothman SL, Yasura K, et al. Degenerative intraspinal cyst of the cervical spine: case report and literature review. *Spine* 2002;27(1):18–22. DOI: 10.1097/00007632-200201010-00029
8. Wildi LM, Kurrer MO, Benini A, et al. Pseudocystic degeneration of the lumbar ligamentum flavum: a little known entity. *J Spinal Disord Tech* 2004;17(5):395–400. DOI: 10.1097/01.bsd.0000109837.59382.0e
9. Kalinindi KKV, Bhat MR, Gupta M, et al. Ligamentum flavum cyst with acute onset motor deficit: a literature review and case series. *Int J Spine Surg* 2020;14(4):544–551. DOI: 10.14444/7072
10. Onofrio BM, Mih AD. Synovial cysts of the spine. *Neurosurgery* 1988;22(4):642–647. DOI: 10.1227/00006123-198804000-00004
11. Machino M, Yukawa Y, Ito K, et al. Cervical degenerative intraspinal cyst: a case report and literature review involving 132 cases. *BMJ Case Rep* 2012;2012:bcr2012007126. DOI: 10.1136/bcr-2012-007126
12. Hatem O, Bedou G, Negre C, et al. Intraspinal cervical degenerative cyst: report of three cases. *J Neurosurg* 2001;95(1 suppl):139–142. DOI: 10.3171/spi.2001.95.1.0139
13. Kao CC, Winkler SS, Turner JH. Synovial cyst of spinal facet. Case report. *J Neurosurg* 1974;41(3):372–376. DOI: 10.3171/jns.1974.41.3.0372
14. Yahara Y, Kawaguchi Y, Seki S, et al. Ligamentum flavum cyst of the cervical spine associated with rheumatoid arthritis. *J Orthop Sci* 2009;14(2):215–218. DOI: 10.1007/s00776-008-1313-8